

De reversed schouder prothese
lustrumcongres

OZL

21 april 2018

s.k.samijo en r. walbeehm


geschiedenis

- Themistocles Gluck +/- 1850
- Pean: 1894
- Charles Neer (anatomisch)
- Eerste generatie: monoblok 1951 (hemiartroplasty voor fracturen).
- 2e generatie; modulair 1972
- 3e generatie: modulair en adapteerbaar 1990

Jules-Émile Péan (29 November 1830 - 20 January 1898)



Charles S. Neer, II, M.D. (1917-2011)




1

adaptable

- Herstel centrum van rotatie
- Optimale weke delen spanning
- Dus gebruik makend van een intacte cuff

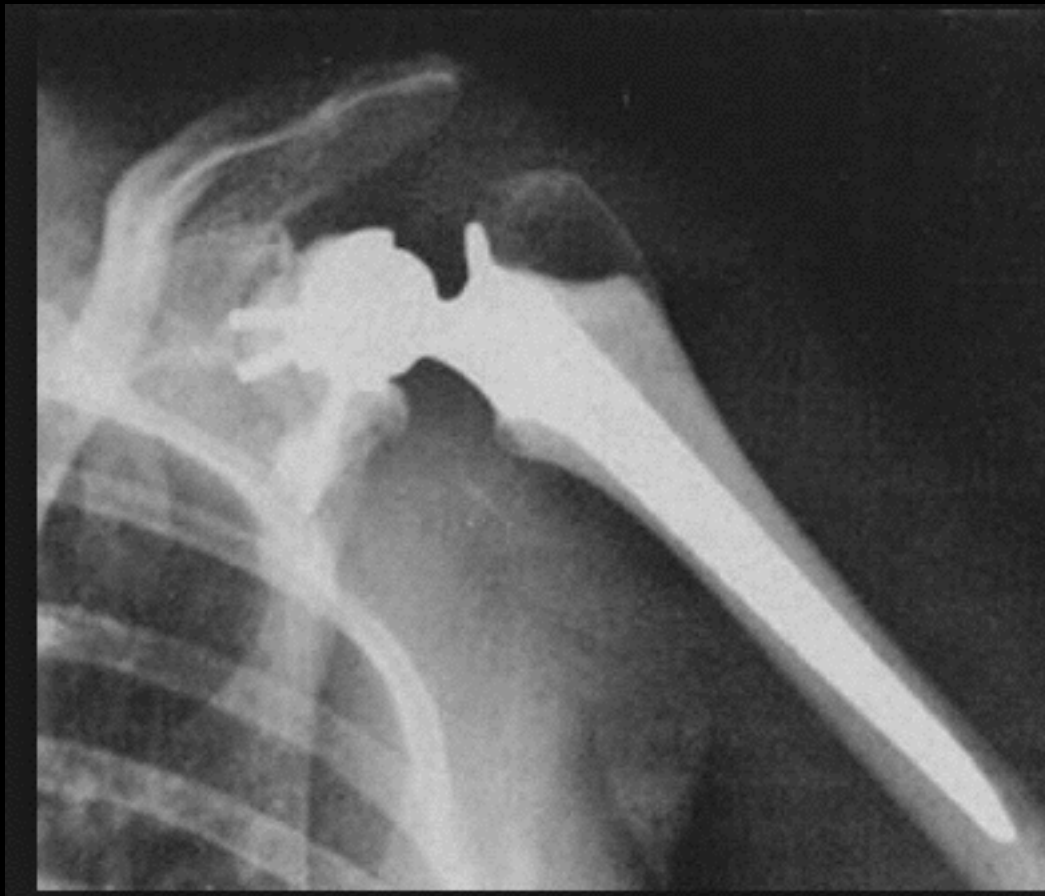Maar...

“... outcomes of shoulder arthroplasty were poorer when rotator cuff was not functional”

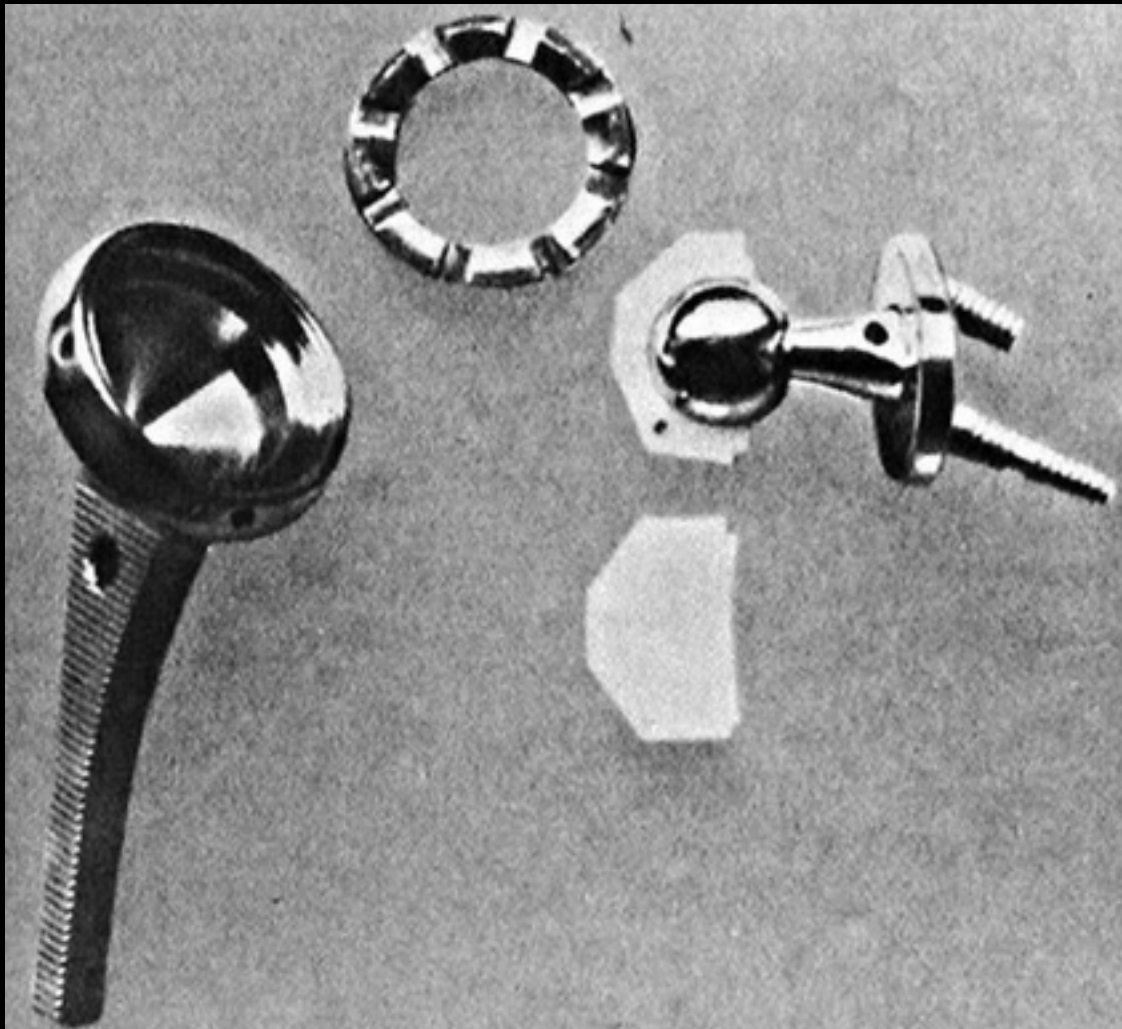


Oplossing..

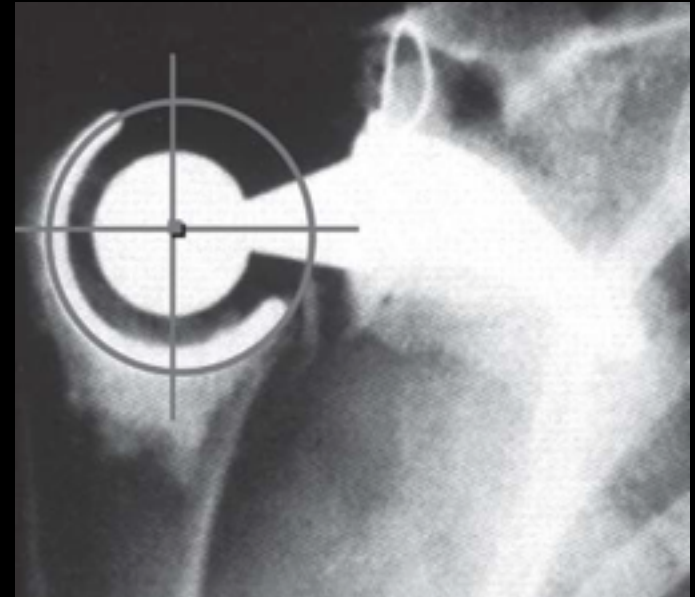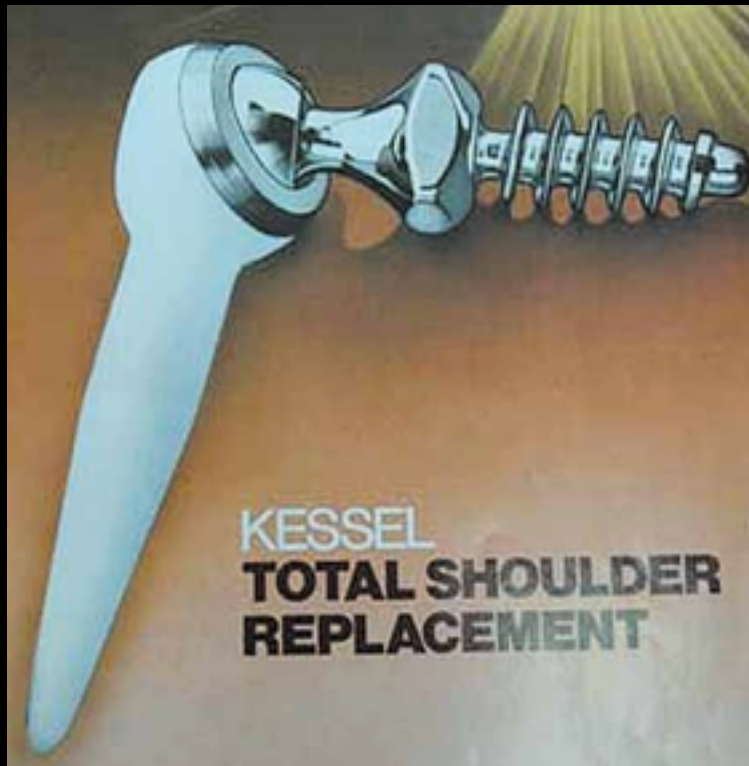
- Zo constraint mogelijk...



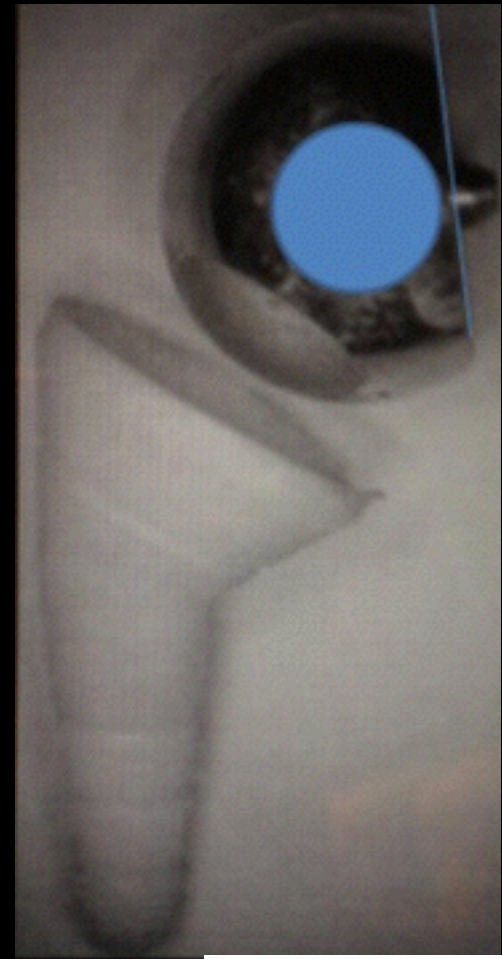Reeve prothese 1972



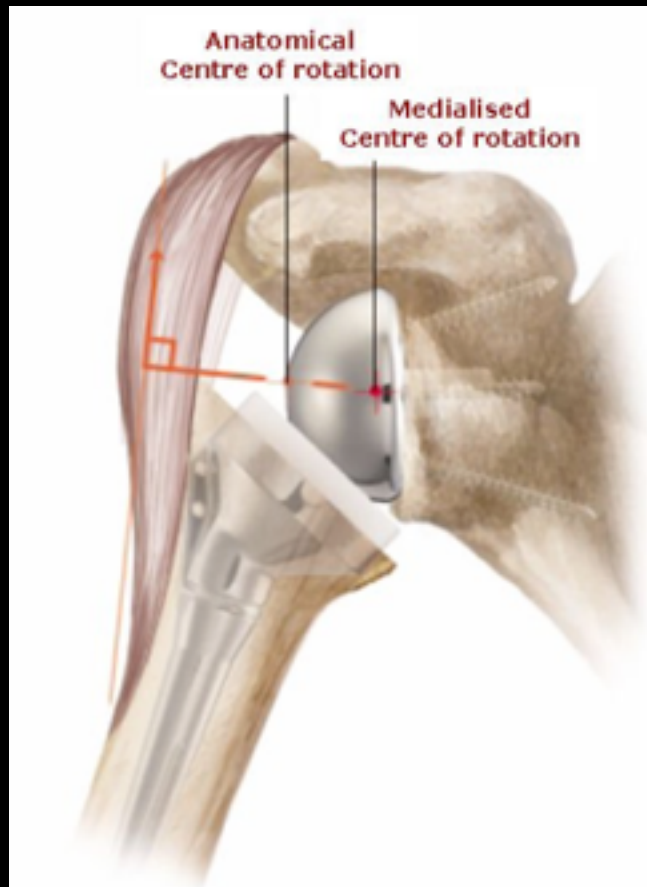
Geschiedenis reversed schouder prothese



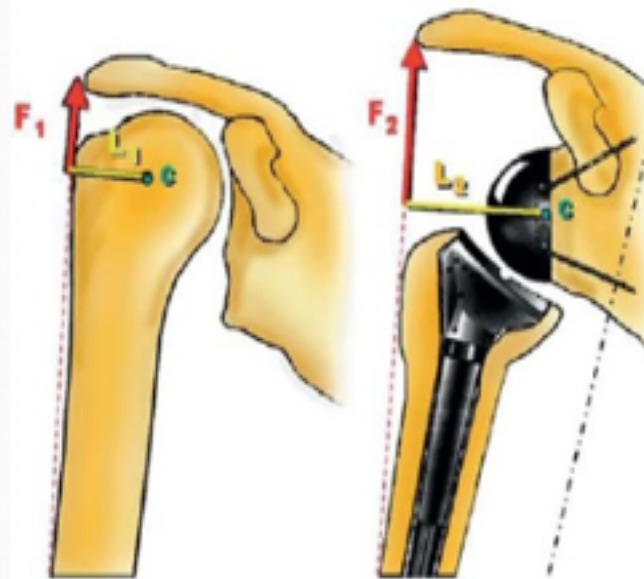
Paul grammont



Reversed shoulder prosthesis



Biomechanical effects of reversed prosthesis



-The lever arm distance (L) is increased and deltoid force (F) is increased by lowering and medializing the centre of rotation which is now also fixed.

-Torque ($F \times L$) in abducting the arm is increased.

-Deltoid tension increased on lifting and lowering arm.

- \uparrow Joint compression.

-105° elevation +.

Reversed schouder prothese



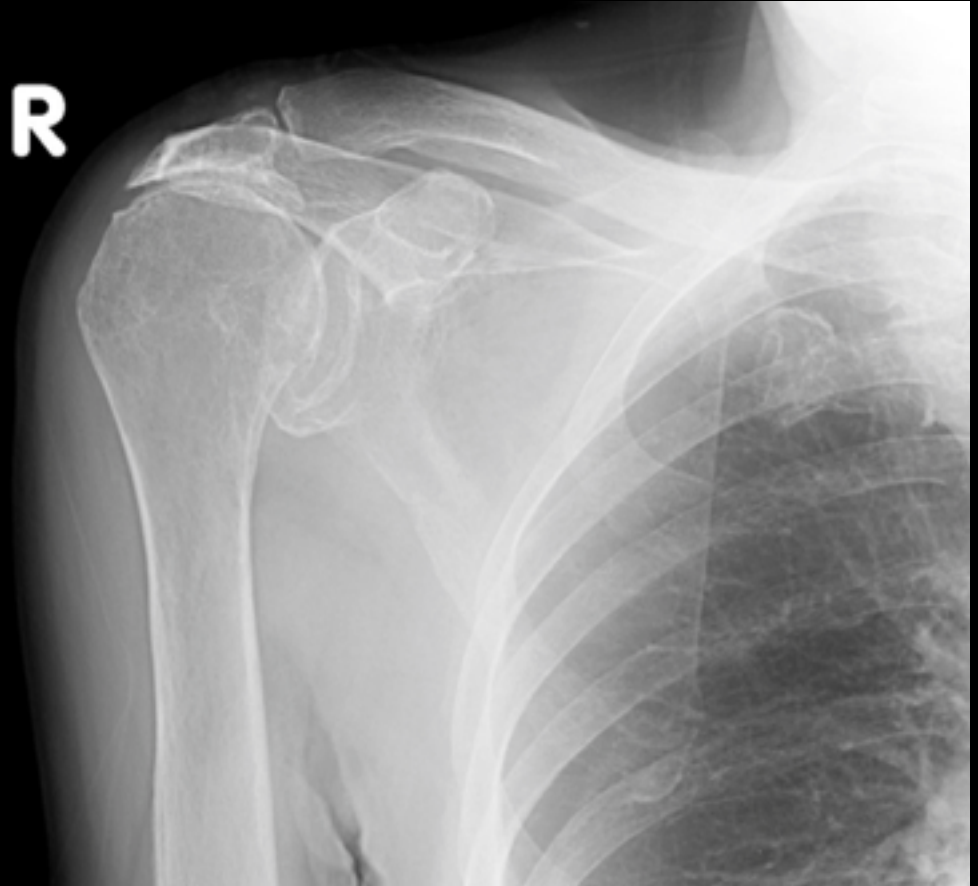Fig. 1

A reverse total shoulder prosthesis. From left to right: the humeral stem and metaphysis, the polyethylene humeral concavity insert, the glenosphere, and the metaglene.

Reversed schouder prothese

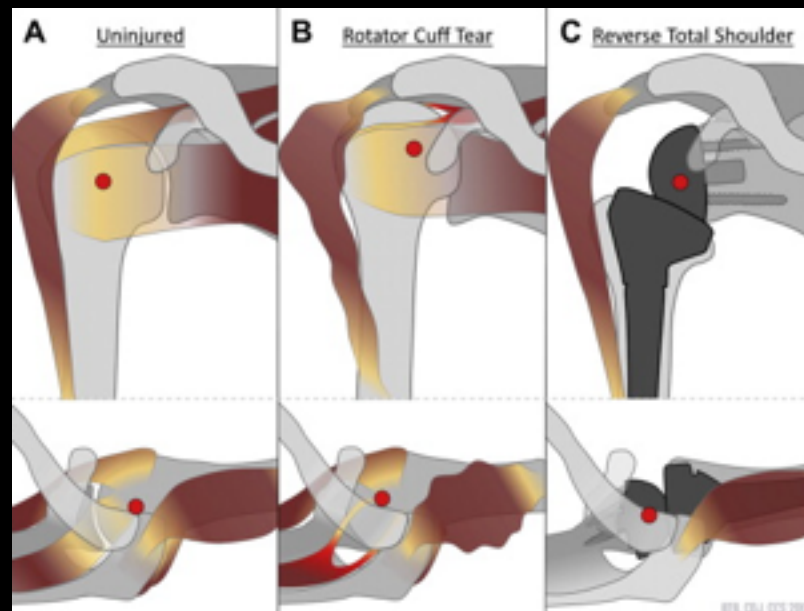
- Cuff artropathie

R



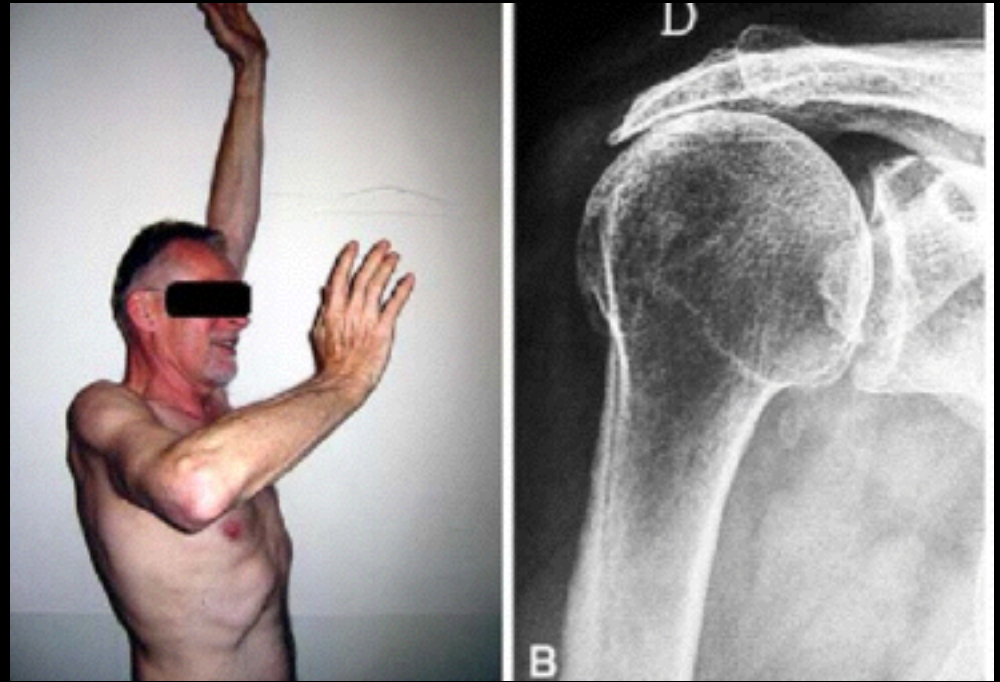
indicatie

- Pseudoparalyse
- Cuff ruptuur
- functionele deltoideus

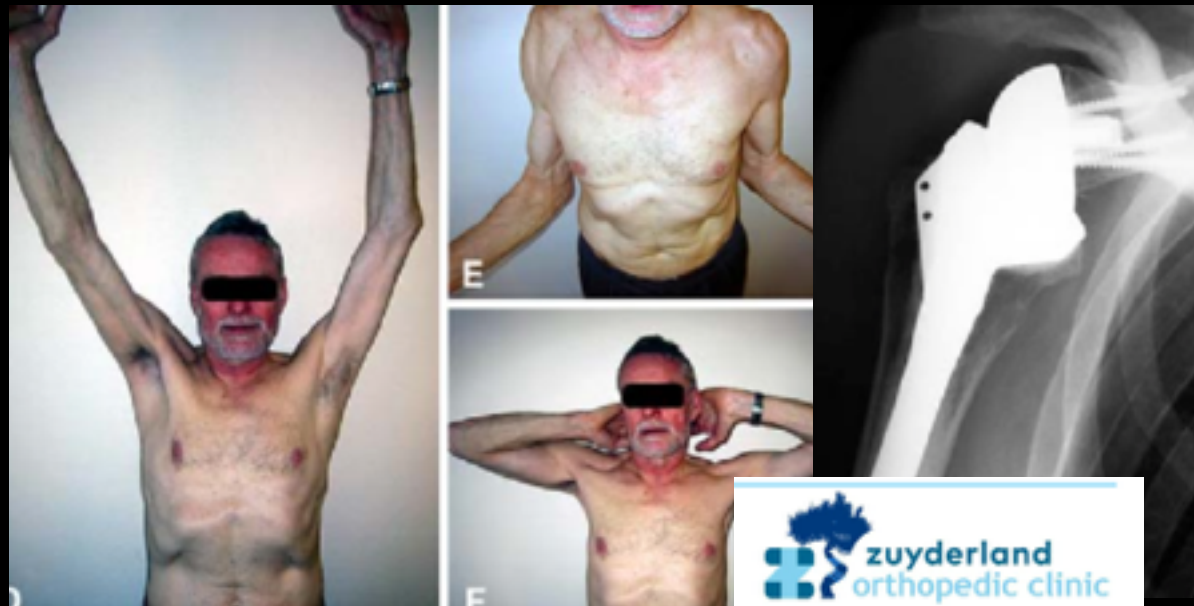

- Pijnloze functie

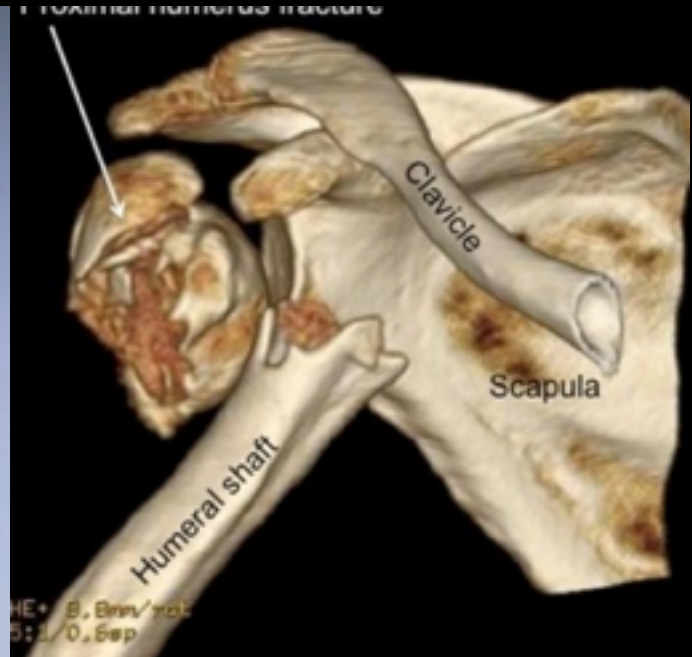
- Hand hoofd



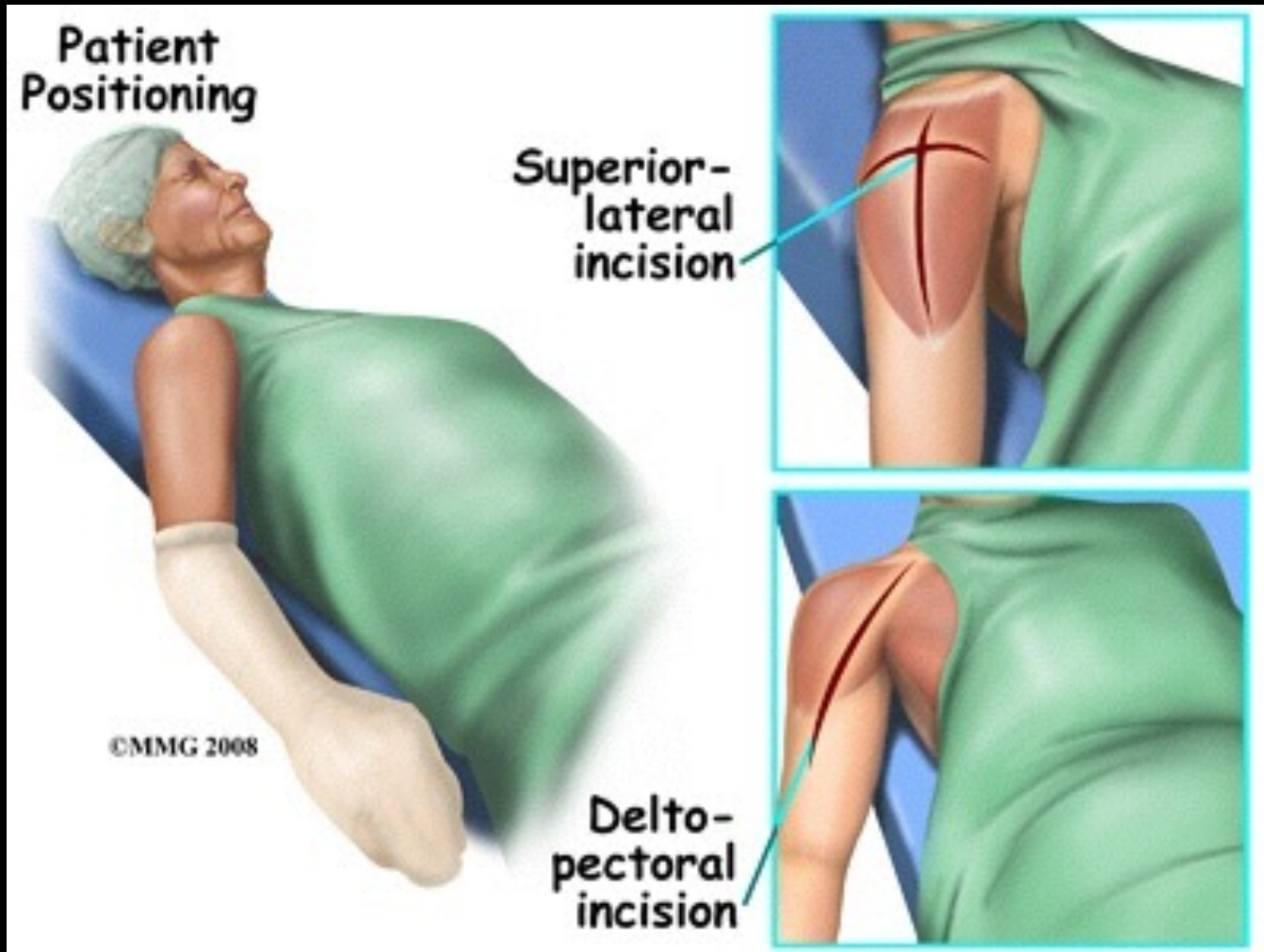
- Hand bil



Reversed fracture prosthesis



Patent ligging



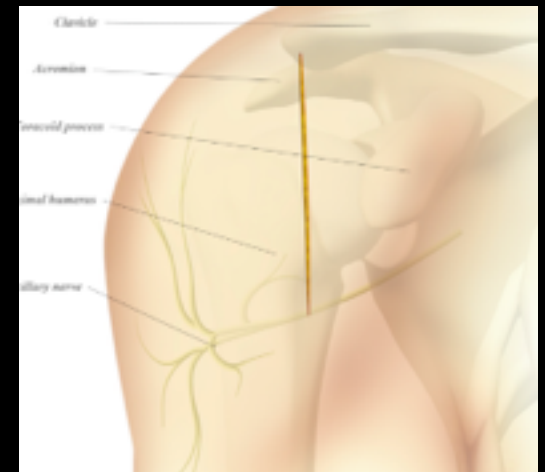
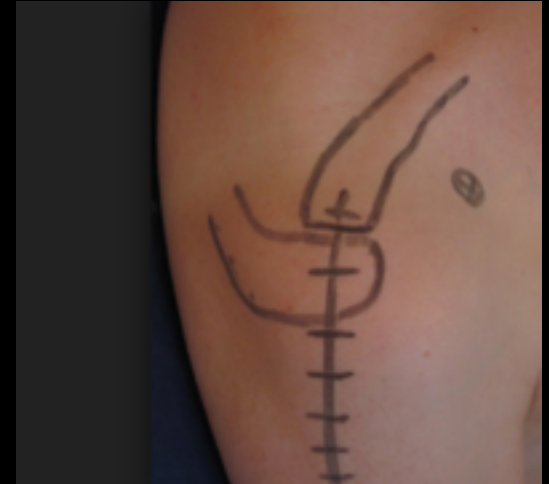Anterosuperiore benaderingen

- Voordeel

- Axiale humerus zicht
- Goed zicht op glenoid
- Geen/minder luxaties

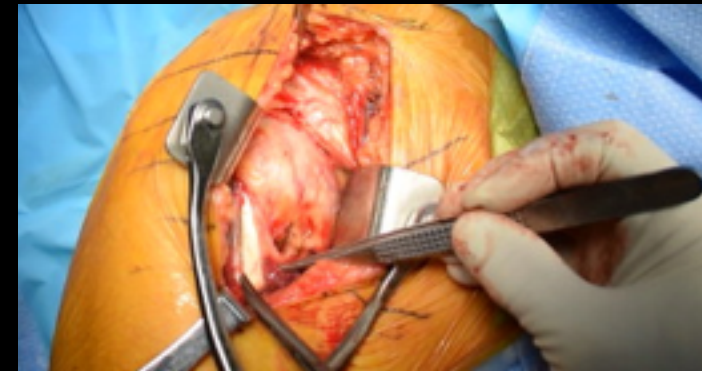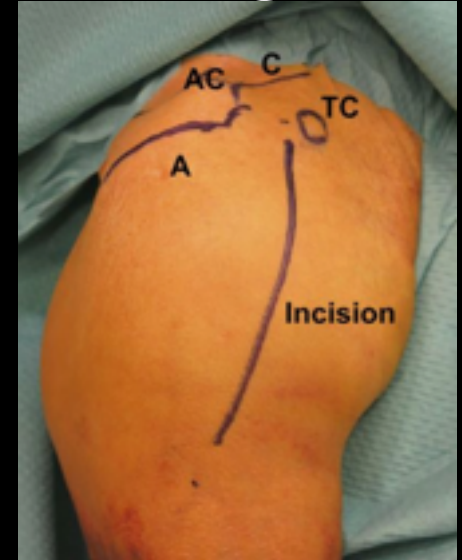
• Nadeel

- Deltoideus beschadiging
- Risico inadequate glenoid plaatsing
- Nervus axillaris beschadiging

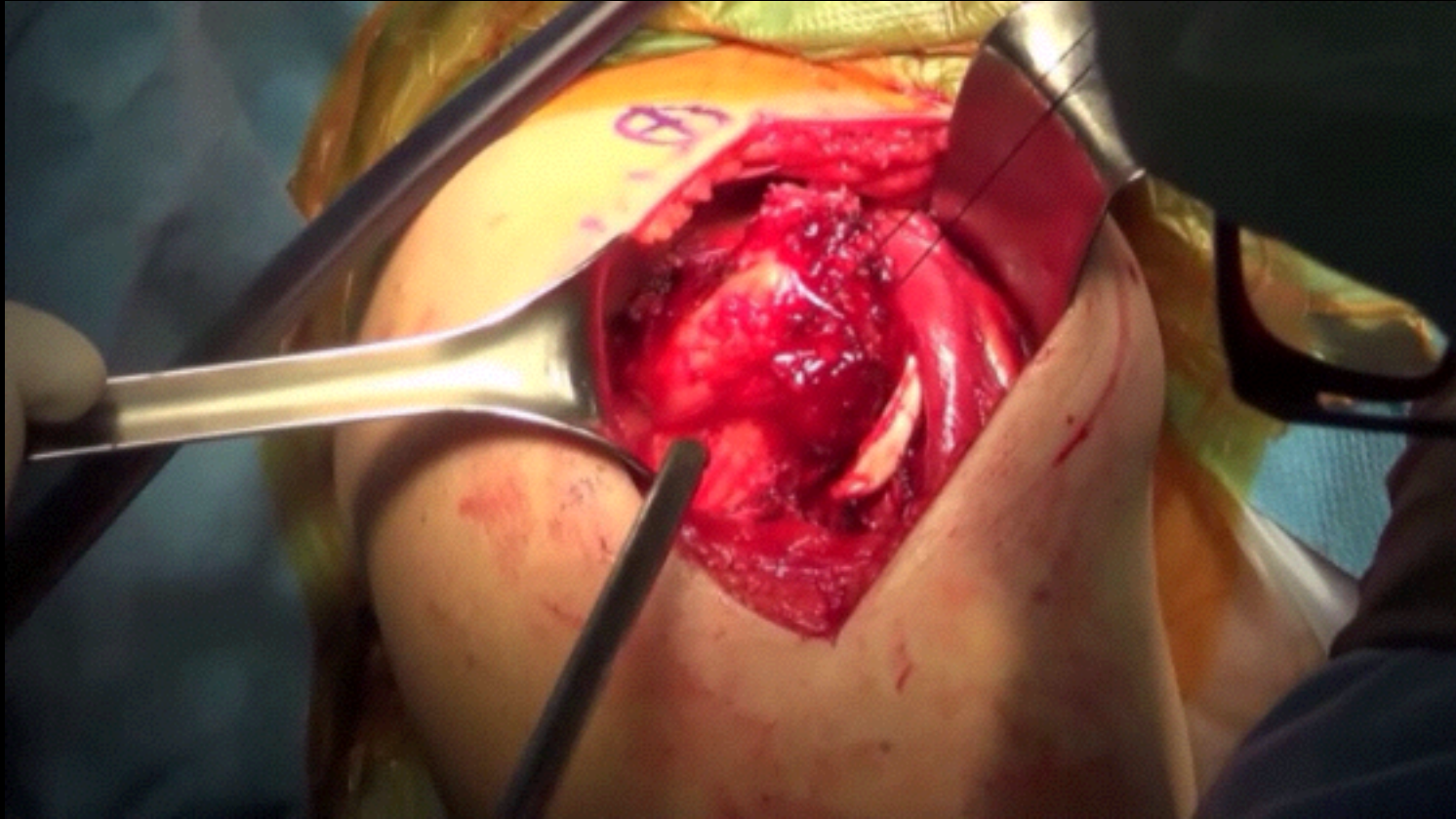


Deltopectorale benadering

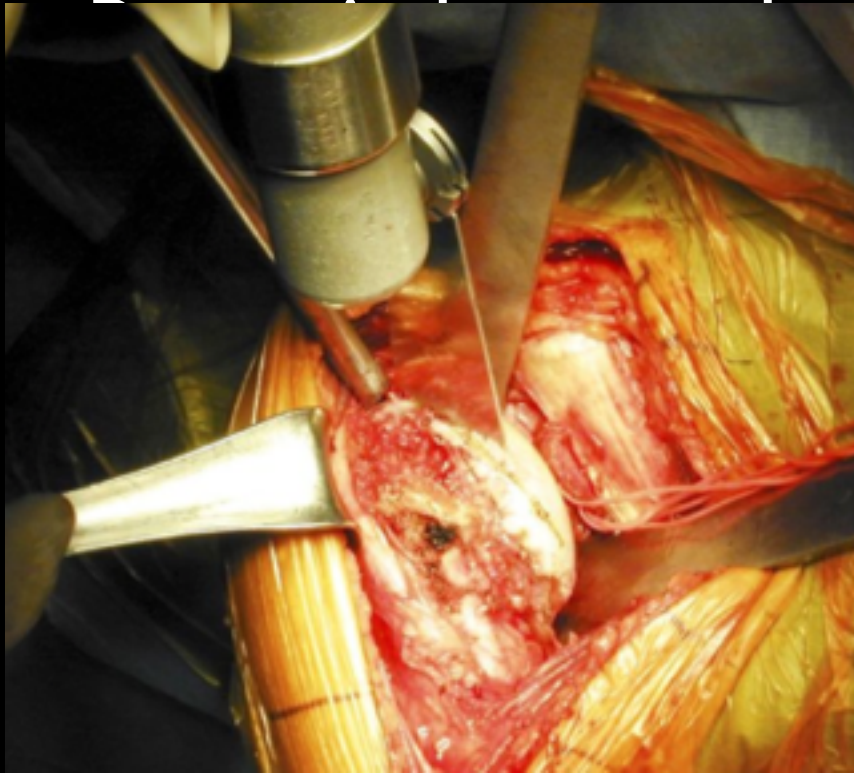
- Voordeel
 - Minimale schade deltoideus
 - Goed bij revisie
- Nadeel
- Subscapularis ladering
- Groter risico op luxatie
- Zicht op glenoid?



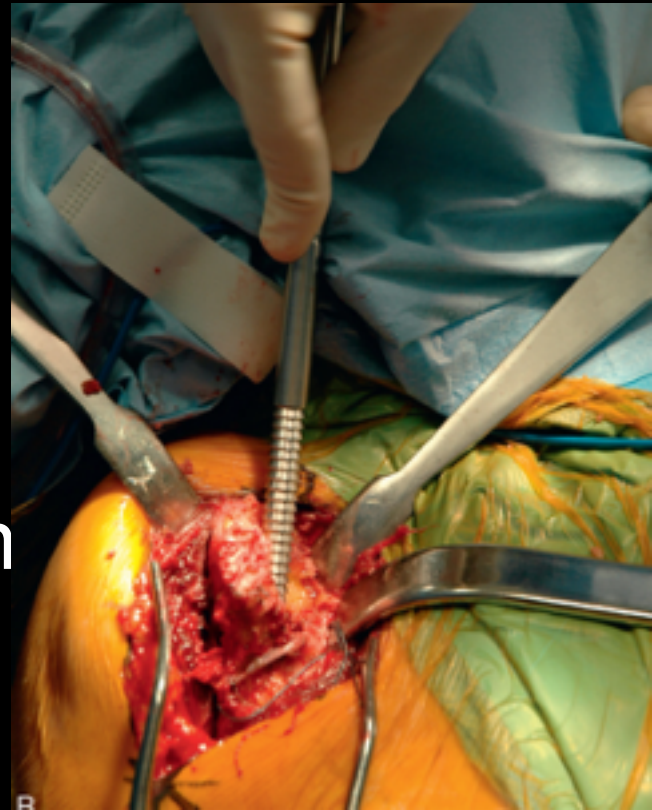Chirurgische procedure: debridement rest cuff



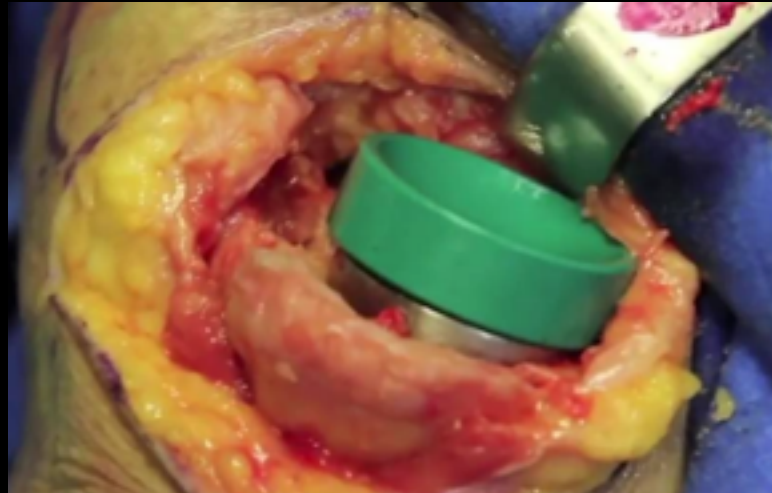
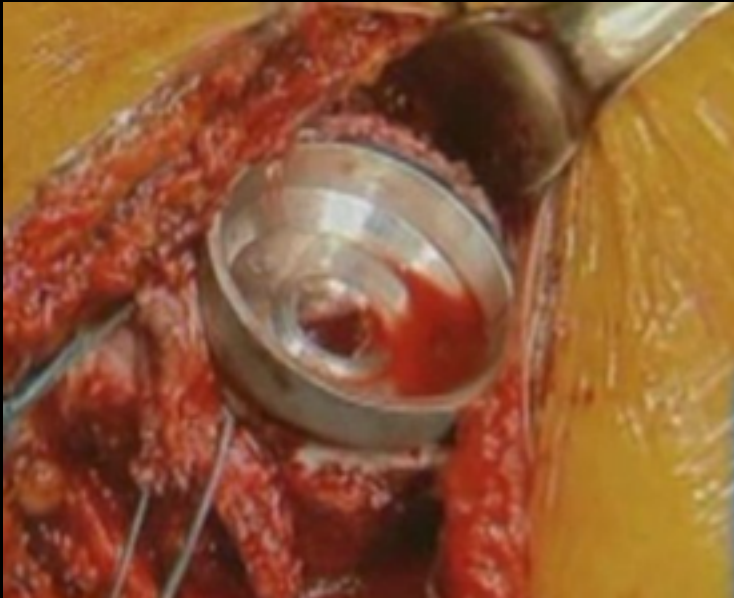
chirurgische procedure: humerus



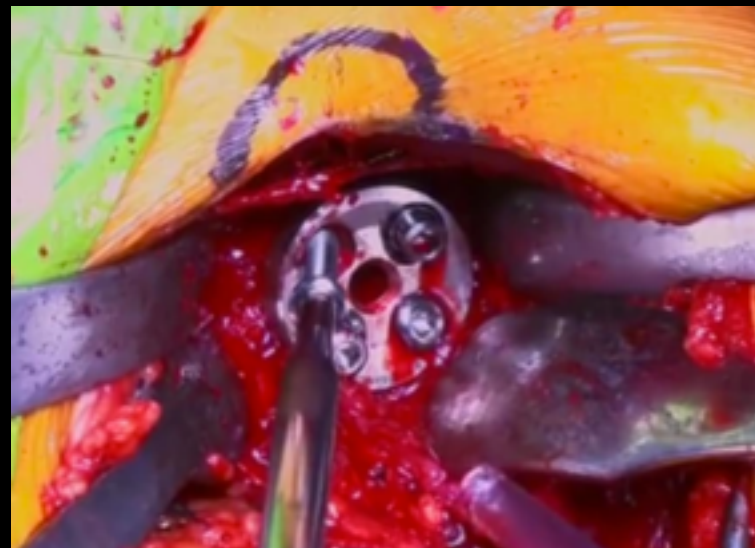
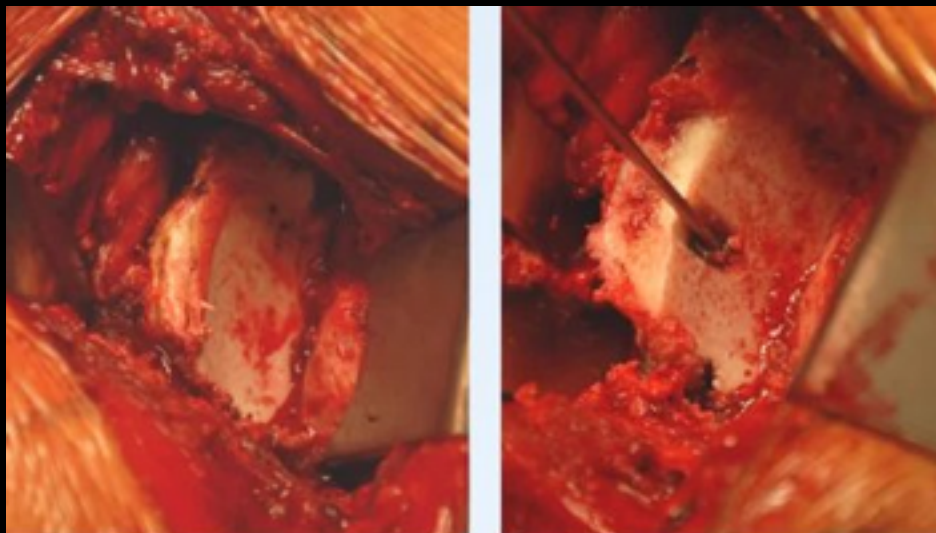
o
en
om



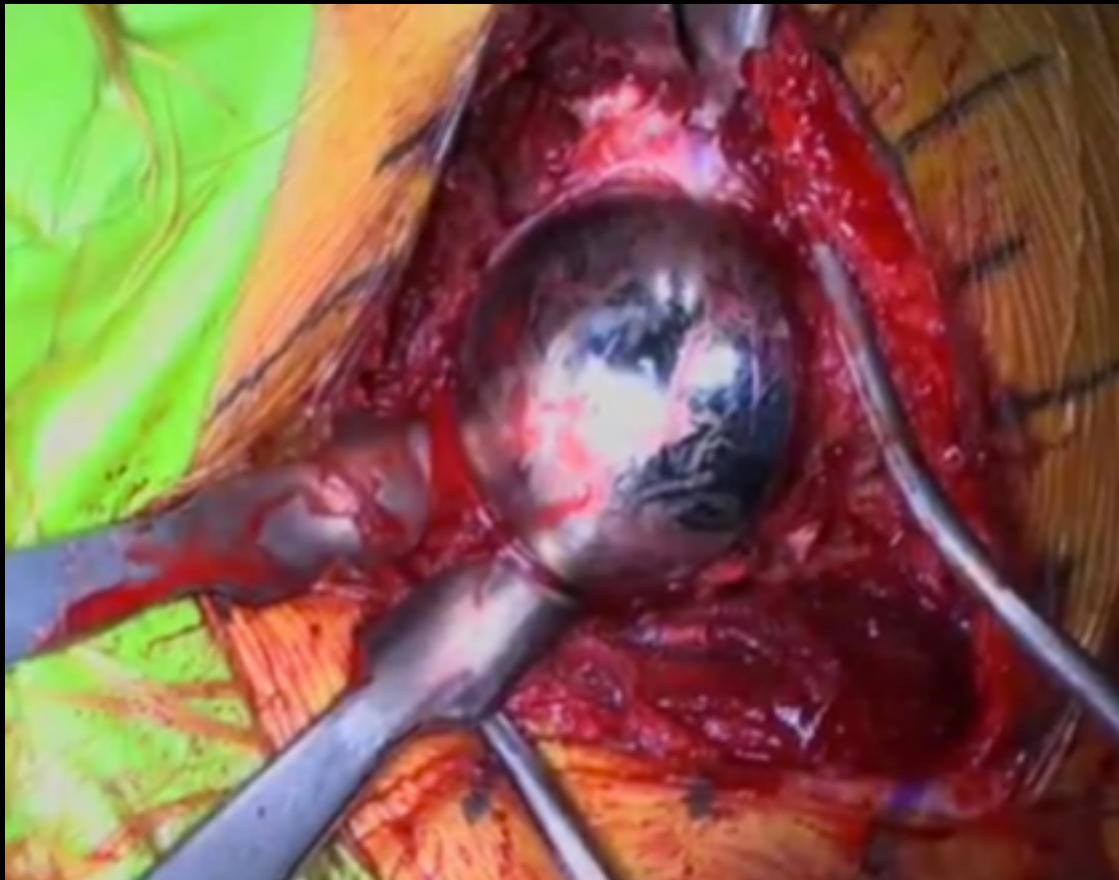
Humerus: implantatie steel



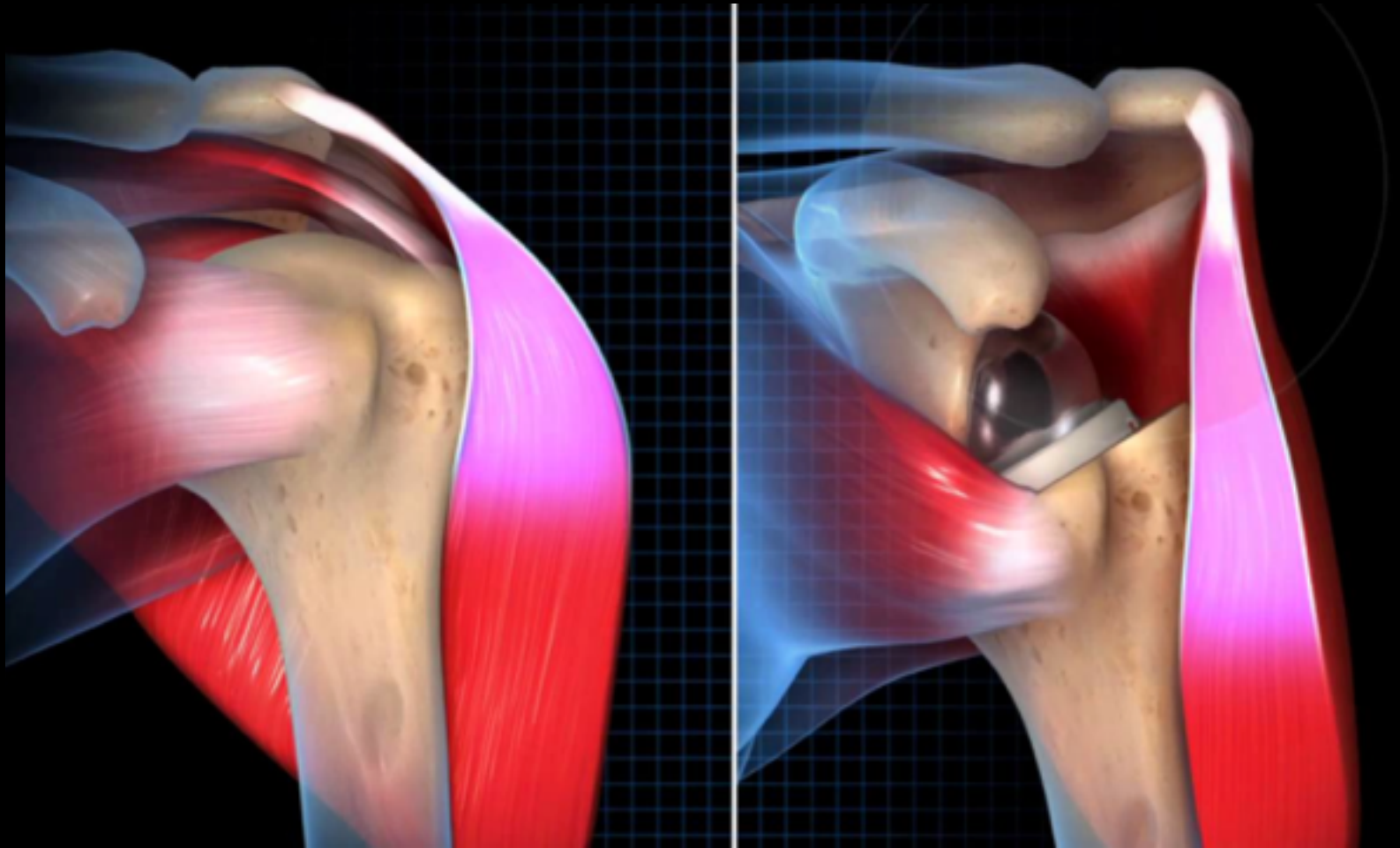
Glenoid resurfacing



Glenoidcomponent plaatsing




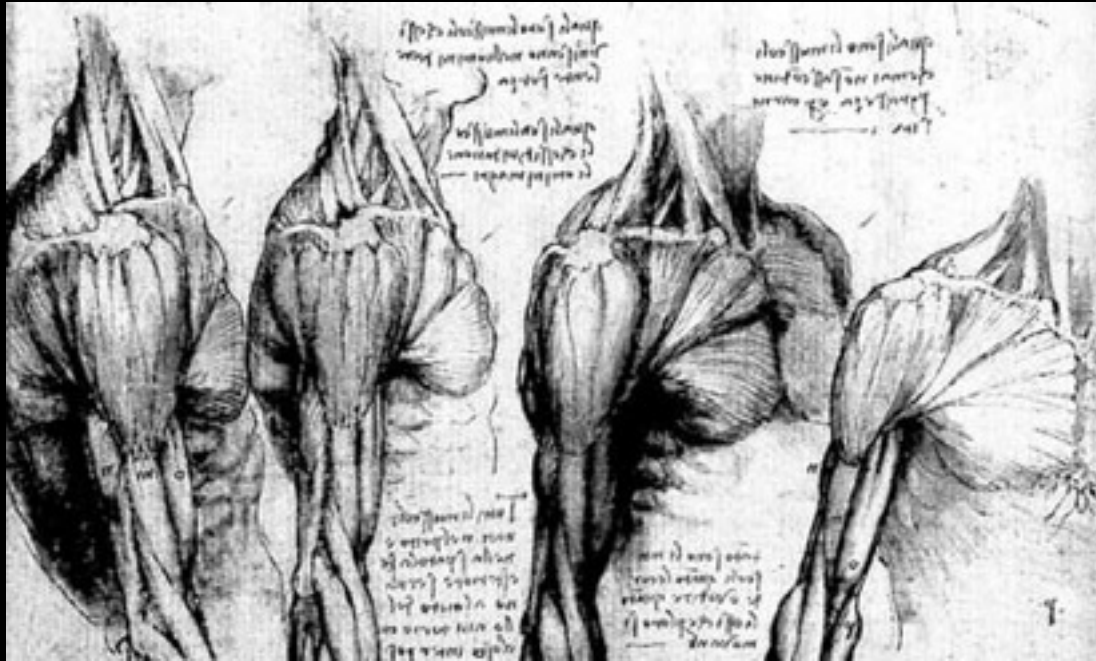
In toto



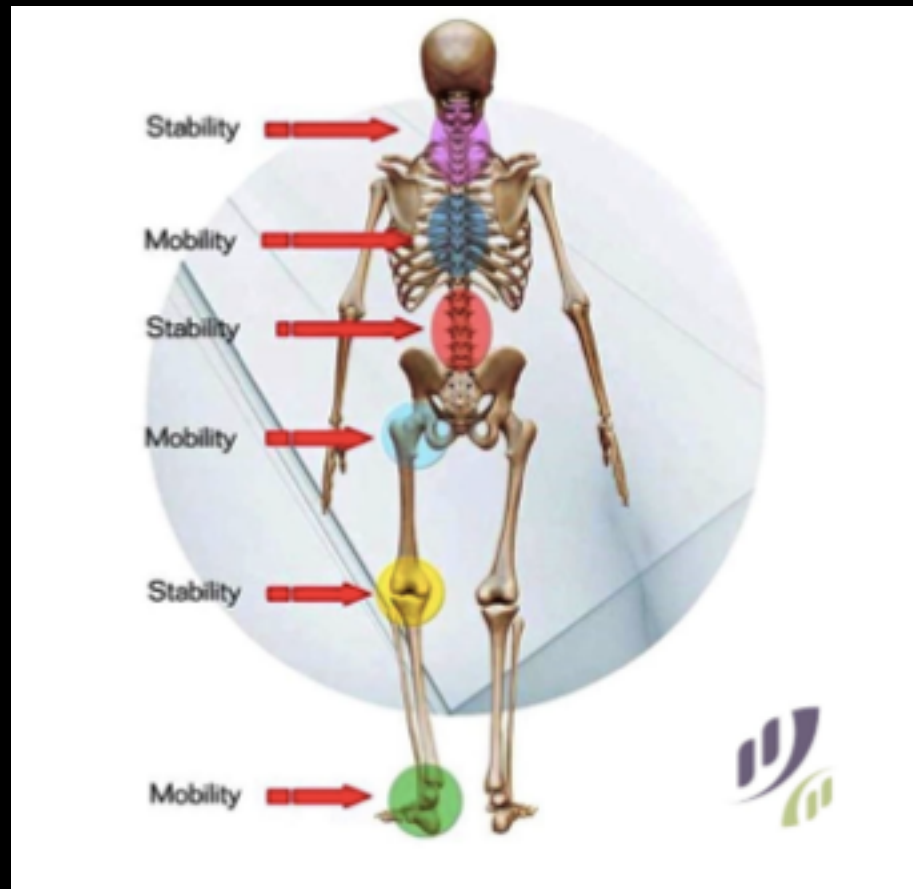
Doelstelling nabehandeling

- Toename beweging: eerst richting scapula daarna anteflexie en abductie
- Stabiliteit
- Scapulaire controle en stabiliteit
- Externe rotatie zwak: maximalisatie
- Uiteindelijk hand hoofd met hand bil bereik

nabehandeling: deel van biomechanische keten



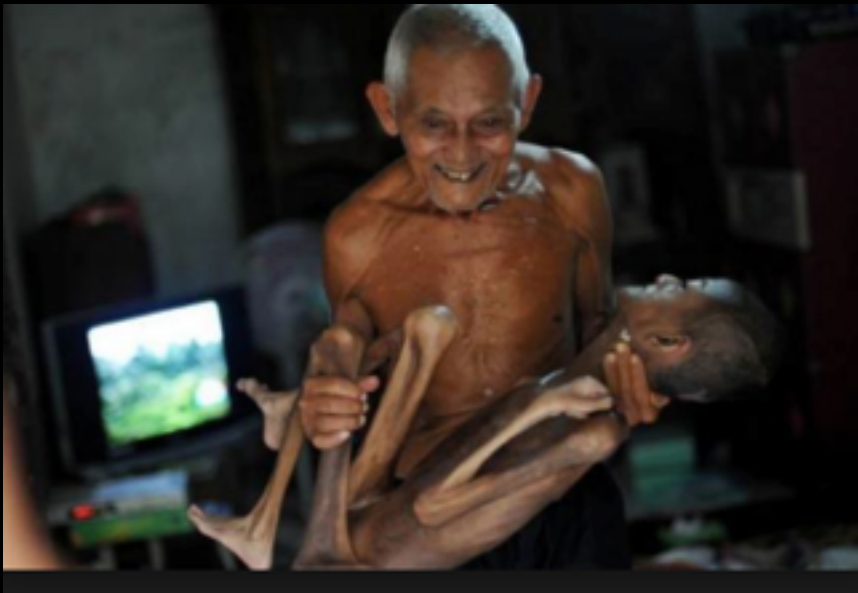...statische en dynamische houding



de patient..



de patient.....

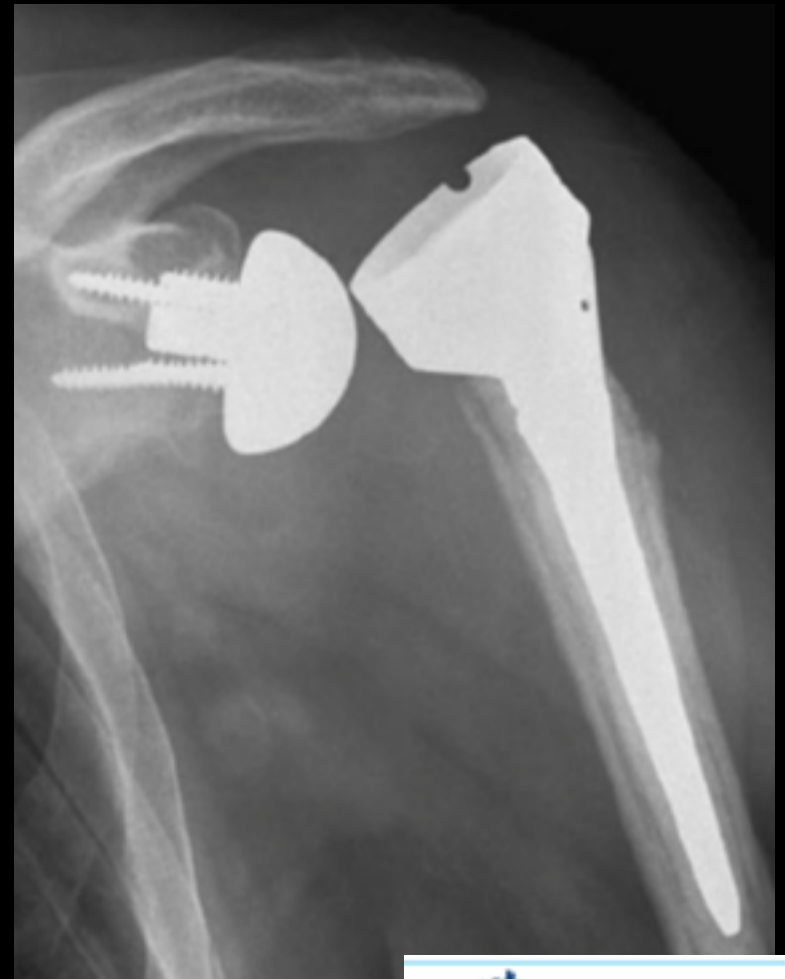
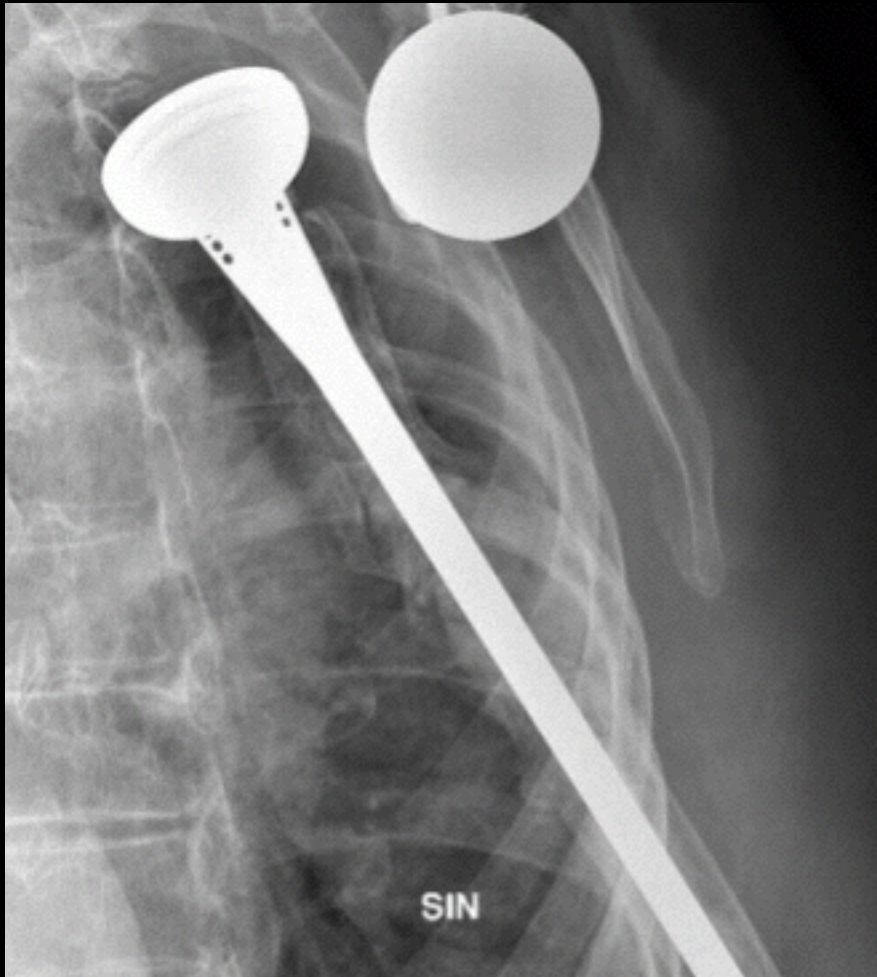

complicatie

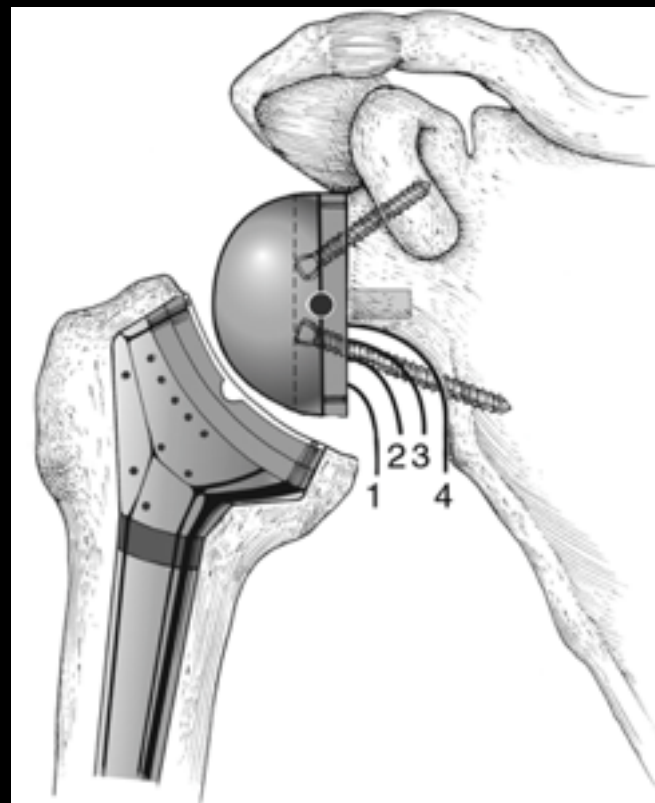
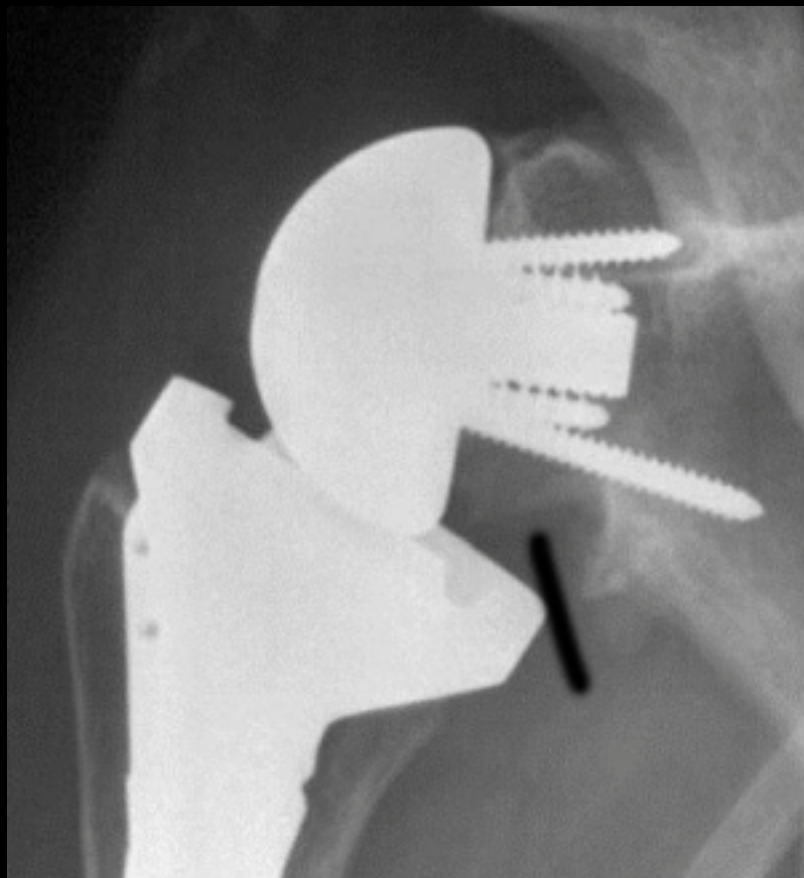
- Dislocatie
- haematoom
- Infect
- Scapular notching
- Neuropraxie
- Acromion fractuur,
- Glenoid loosening
- Humeral loosening
- Geen abductie boven 90 graden



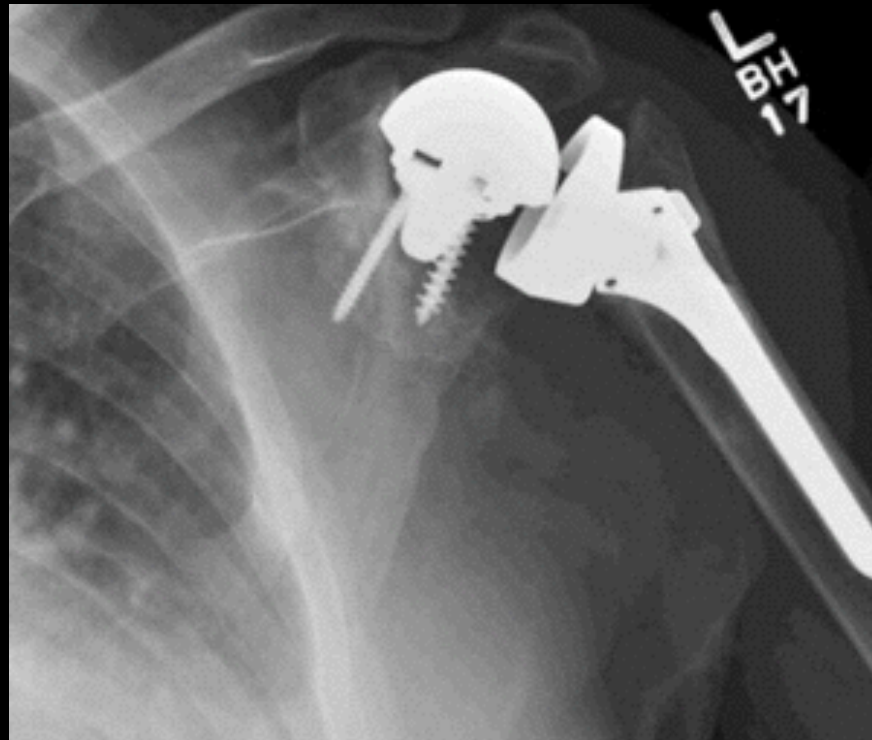
luxatie



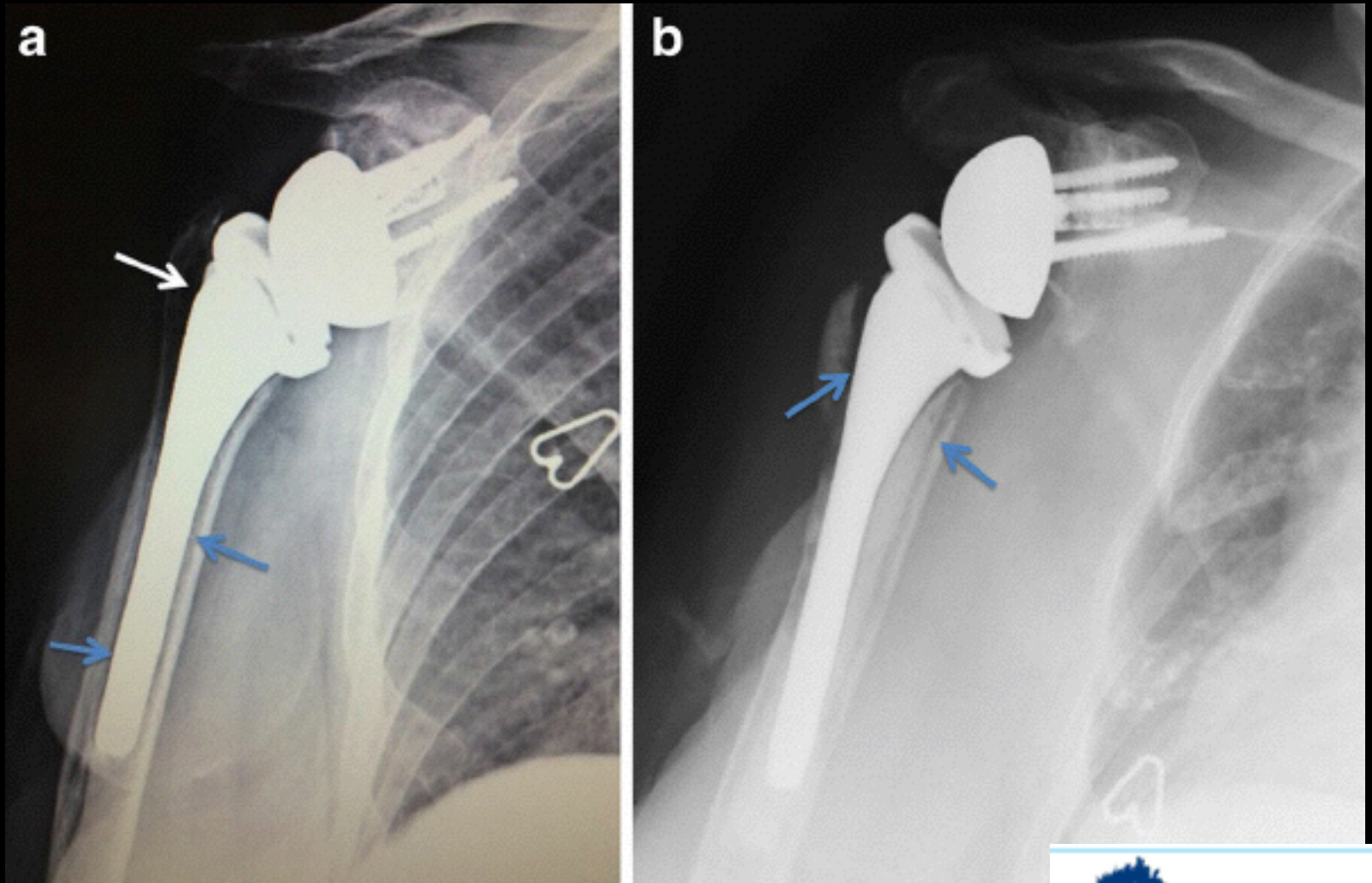
notching



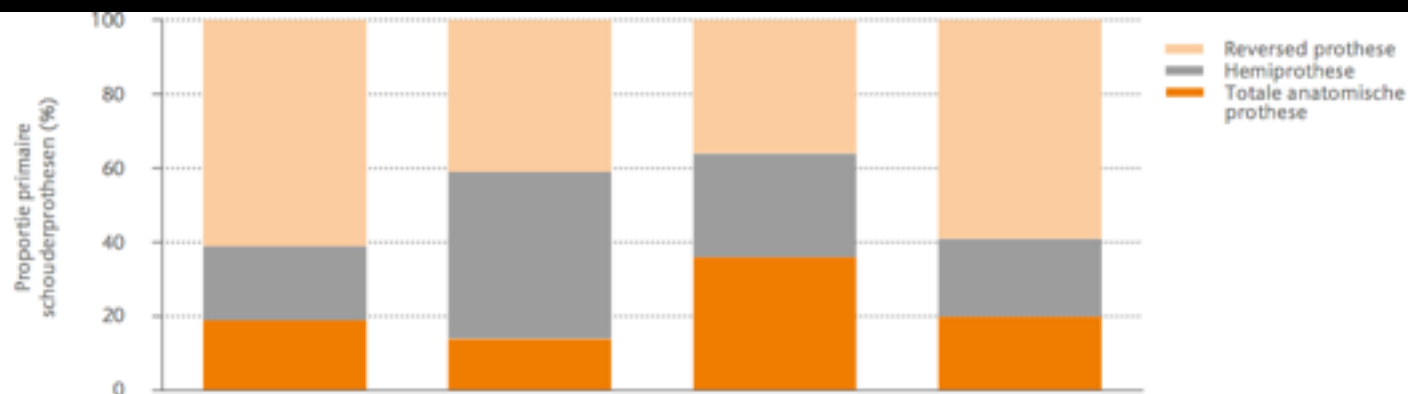
Glenoid loosening



Humerale loslating



In nederland 2014



Type instelling

Algemeen

UMC

ZBC

Totaal

Soort schouderprothese

Reversed prothese (%)	61,1	41,2	35,8	59,5
Hemiprothese (%)	19,5	44,7	28,4	20,8
Totale anatomische prothese (%)	19,4	14,1	35,8	19,7

Totaal (n)

1.907

85

67

2.059

© LROI 2015

Figuur 7.3 Soort primaire schouderprothese (proportie (%) per categorie) per type instelling in Nederland in 2014.

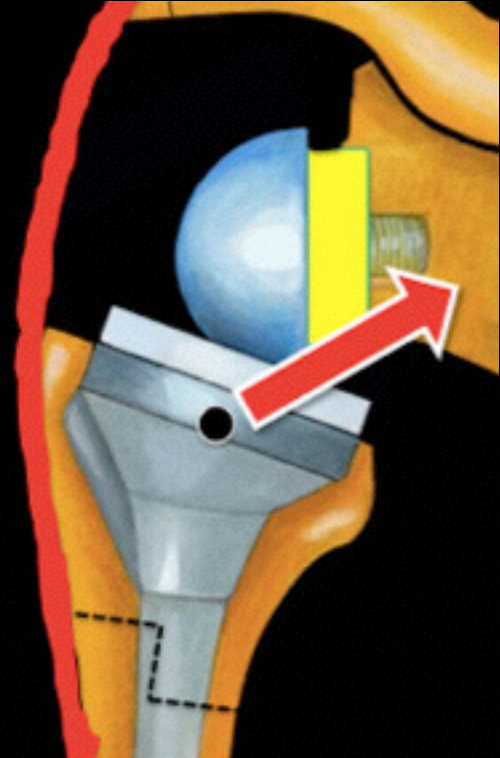
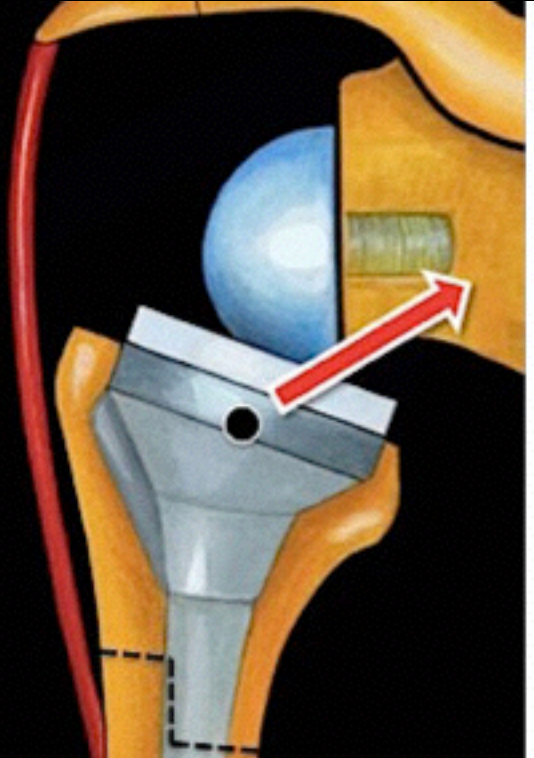
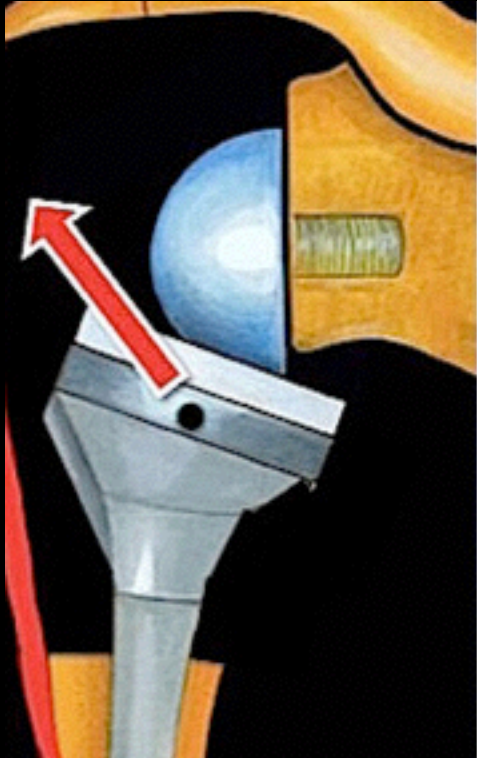
Algemeen: algemeen ziekenhuis; UMC: universitair medisch centrum; ZBC: zelfstandig behandelcentrum.

J Bone Joint Surg Am. 2017 Mar 15;99(6):454-461. doi: 10.2106/JBJS.16.00223.
Long-Term Outcomes of Reverse Total Shoulder Arthroplasty: A Follow-up of a Previous
Study.

[Bacle G1, Nové-Josserand L, Garaud P, Walch G.](#)

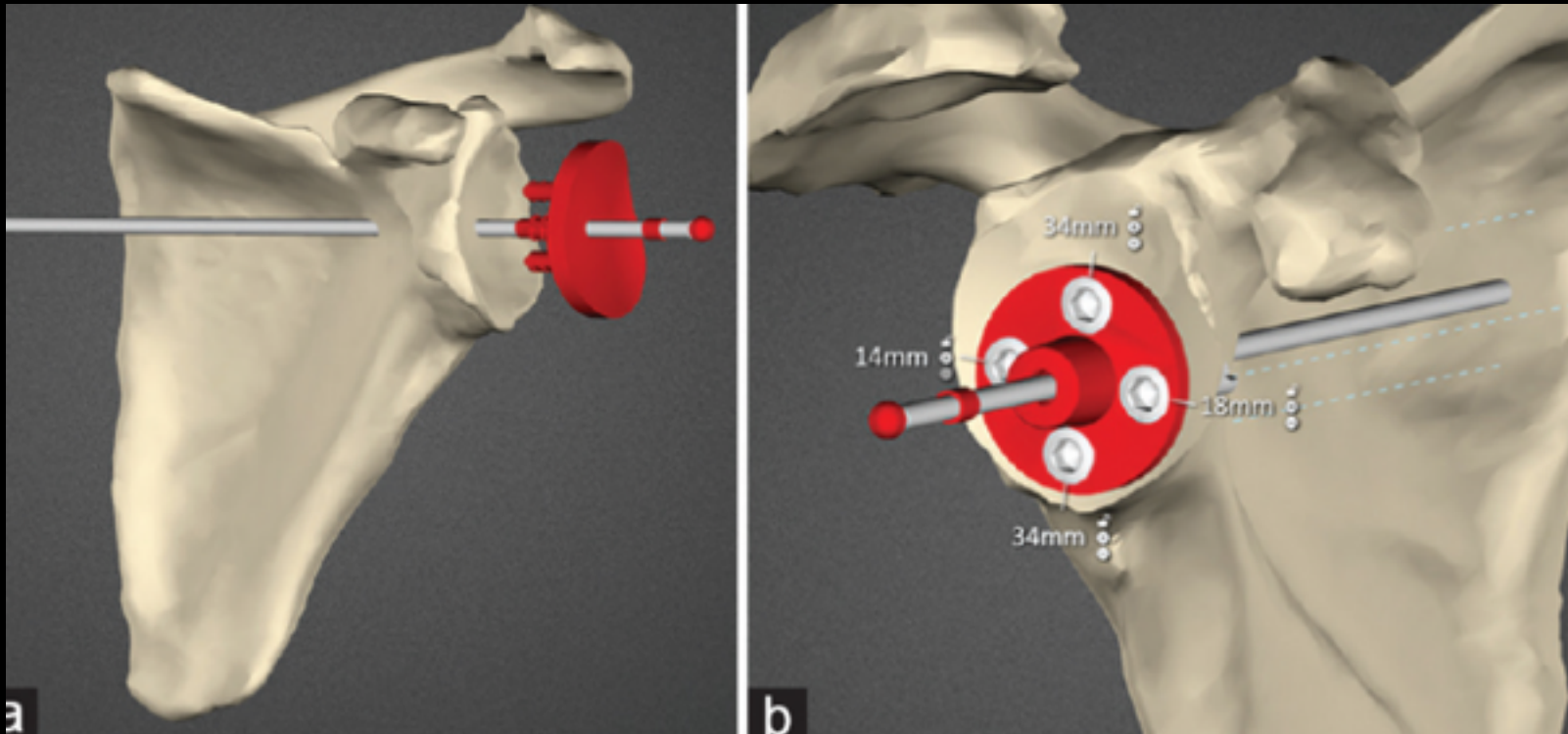
RESULTS: The original report included the outcomes for 186 patients (191 RTSAs) who had been followed for a mean of 40 months. In the present study, in which the mean duration of follow-up was 150 months, follow-up clinical evaluations were available for 84 patients (87 prostheses) and radiographic assessments were available for 64 patients (67 prostheses). Seventy-seven patients (79 prostheses) had died before the 10-year follow-up, and 17 patients (17 prostheses) had been lost to follow-up. The mean absolute and relative Constant scores (and standard deviations) were 55 ± 16 points and 86 ± 26 points, respectively, with both having decreased significantly compared with the scores at the medium-term follow-up evaluation (at a minimum of 2 years) ($p < 0.001$ and $p = 0.025$, respectively). Forty-nine shoulders (73%) exhibited scapular notching. Forty-seven complications (29%) were recorded, with 10 cases (10%) occurring after 2 years. Sixteen (12%) of the original patients underwent revision surgery. The 10-year overall prosthetic survival rate using revision as the end point was 93%.

bioRSA



ontwikkeling

- Patient specific instrumentation



Botverlies glenoid



Trabecular metal



conclusie

- De reversed schouder prothese is een goede chirurgische optie bij cuff artropathie en pseudoparalyse
- De 10 jaars overleving zit rond de 90%
- De prothese is nog steeds in ontwikkeling

bedankt voor uw aandacht

