

# Operatieve behandeling Anterieure Schouderinstabiliteit

R.Walbeehm/S.Samijo  
Orthopedie Zuyderland

Disclosure-slide voor sprekers op nascholingsbijeenkomsten

<b>Disclosure belangen spreker</b>	
<b>(potentiële) Belangenverstrengeling</b>	<b>Geen / Zie hieronder</b>
<b>Voor bijeenkomst mogelijk relevante relaties met bedrijven<sup>1</sup></b>	<b>Bedrijfsnamen</b>
<ul style="list-style-type: none"><li>• Sponsoring of onderzoeksgeld<sup>2</sup></li><li>• Honorarium of andere (financiële) vergoeding<sup>3</sup></li><li>• Aandeelhouder<sup>4</sup></li><li>• Andere relatie, namelijk ...<sup>5</sup></li></ul>	<ul style="list-style-type: none"><li>• <b>Geen</b></li><li>• <b>Geen</b></li><li>• <b>Geen</b></li><li>• <b>Geen</b></li></ul>

# Disclosures

- Geen

# Zuyderland ziekenhuis

- Fusie ziekenhuis Atrium-Orbis
- 15 orthopedisch chirurgen
- Specialisaties
  - Chirurgie bovenste extremiteit
  - Traumatologie
  - Sport orthopedie
  - Wervelkolom chirurgie
  - Heupprothesiologie + revisie chirurgie
  - Knieprothesiologie + revisie chirurgie
  - Voet/enkel chirurgie

MUN 13-31 GLA 77:44 | TMO REVIEW

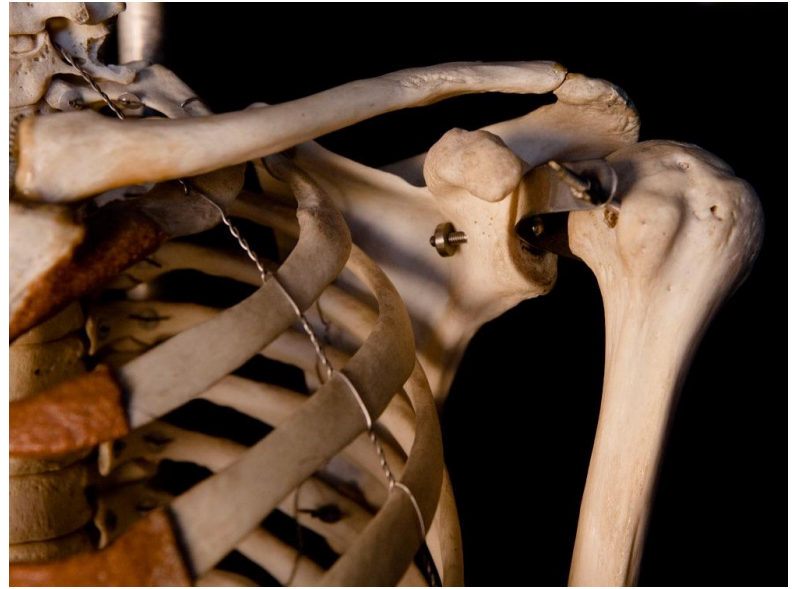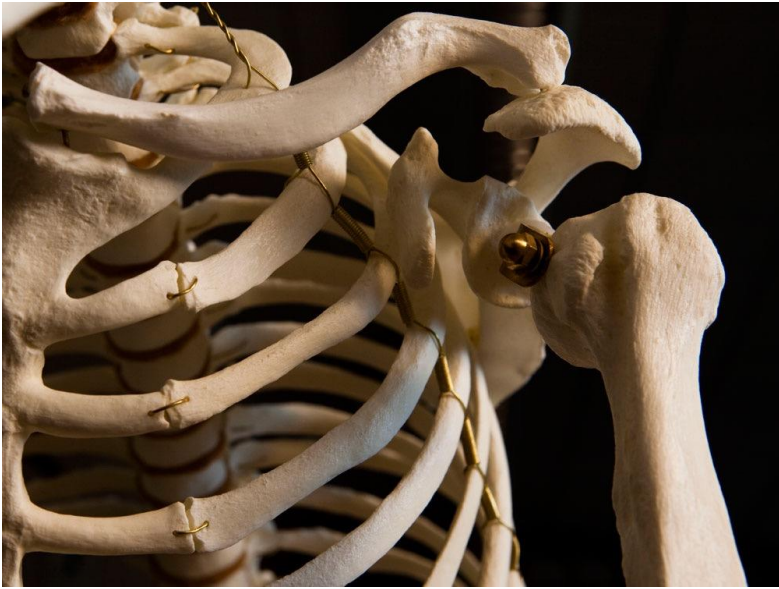COPA AMERICA  
Chile 2015  
10 DAYS LEFT



beIN HD  
SPORTS



**USA SEVENS RUGBY**  
MARCH 4 - 6 | LAS VEGAS



# Schouder feiten

- Relatief weinig benige begrenzing
- Enorme beweeglijkheid
- Van grote gewrichten meeste luxaties
- Anterieure luxaties 90% van alle schouderluxaties
- Recidief kans 72%-96% (jonge actieve patiënten - sporters)
- Recidief luxatie geeft verhoogde kans op chondropathie
- 50% schouderluxatie tussen 15-29 jaar

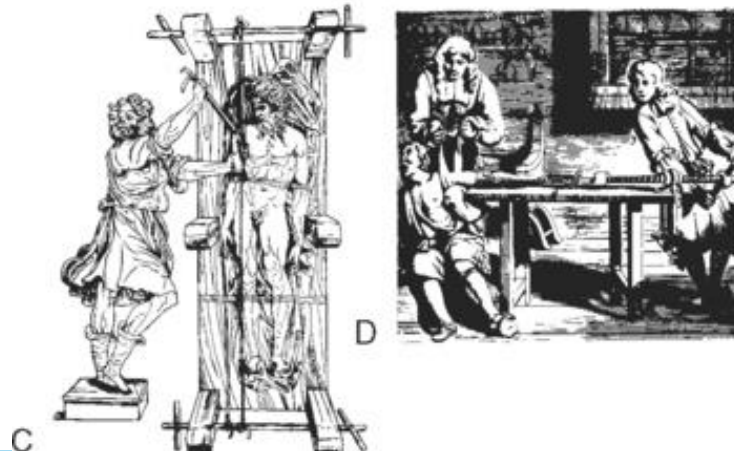
- Level 1 evidence: jonge patiënten met een eerste traumatische schouderluxatie chirurgisch te stabiliseren.



# Operatieve behandeling

- Hippocrates 460 - 377 v.C.

“Niet de arts maar het lichaam geneest de ziekte.”



# Operatieve behandeling

**Anatomisch:**

**Maken wat kapot is**

**Niet-anatomisch:**

**Structuren verkorten of  
strakker maken ongeacht  
functie**

# Operatieve behandeling

**Table I** History of anterior shoulder stabilization surgery

## Open procedures

### Open anatomic repair

Sutures (Bankart)

Staples

Soft-tissue reconstruction

Fascia lata autograft (Gallie)

Muscular transposition of subscapularis  
(Magnusson-Stack)

Shortening of subscapularis and anterior capsule  
(Putti-Platt)

### Osseous glenoid reconstruction

Bristow

Latarjet

Iliac crest autograft (Eden-Hybbinette)

Distal tibia allograft

### Corrective osteotomy

Proximal humerus (Weber)

Glenoid (Meyer-Burgdorff)

### Open capsular imbrication

Laterally based inferior capsular shift (Neer and Foster)

Medially based inferior capsular shift (Altchek)

Vertical capsulotomy

Horizontal capsulotomy

## Arthroscopic procedures

### Arthroscopic anatomic repair

Staples

Transosseous sutures

Metallic rivet

Bioabsorbable tack

Suture anchors

### Arthroscopic capsular imbrication

Thermal capsulorrhaphy

Split and shift

Multi-pleated capsular plication

Posteroinferior capsular plication

Rotator interval closure

### Arthroscopic Latarjet

### Targeted management of Hill-Sachs lesions

Humeral head or femoral head allograft

Disimpaction

Partial resurfacing arthroplasty

Hemiarthroplasty

Arthroscopic remplissage

# Operatieve behandeling

- Labrumletsel:  
Arthroscopisch labrum  
herstel
- Glenoidschade:  
Latarjet procedure
- Hill Sachs lesie:  
Arthroscopische  
remplissage

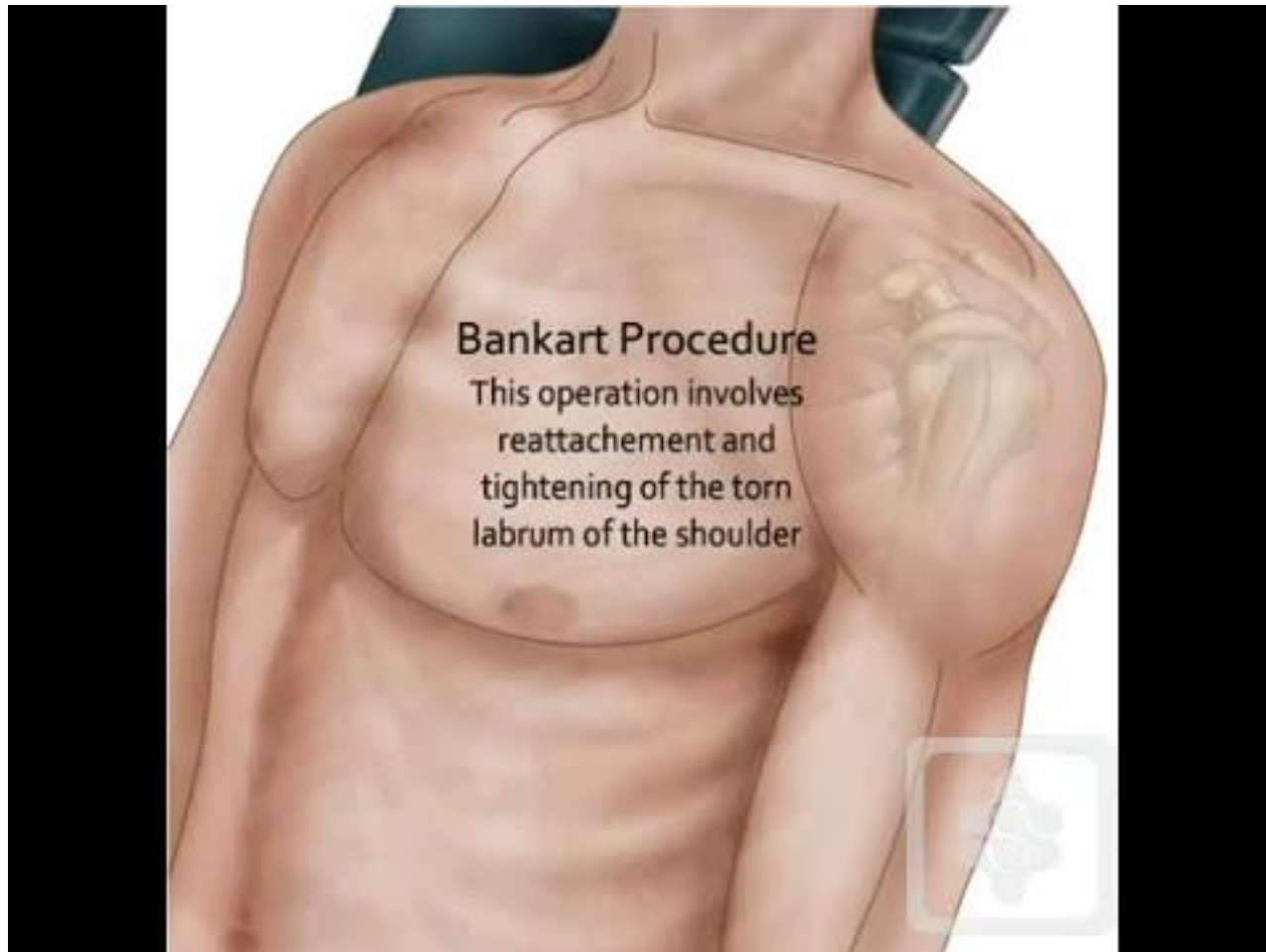
## Instability Severity Score

<i>Variable</i>	<i>Parameter</i>	SCORE
AGE	< 20 years	2
	> 20 years	0
DEGREE OF SPORTS PARTICIPATION	Competitive	2
	Recreational/none	0
TYPE OF SPORT PARTICIPATION	Contact/forced overhead	1
	Other	0
SHOULDER HYPERLAXITY	Hyperlaxity (anterior/inferior)	1
	Normal	0
HILL SACHS ON AP XRAY	Visible on external rotation	2
	Not visible on external rotation	0
GLENOID CONTOUR LOSS ON AP XRAY	Loss of contour	2
	No lesion	0
<i>Clinical Implications</i>		<i>Total Possible = 10</i>
An acceptable recurrence risk of 10% with arthroscopic stabilization.		<b>&lt; 6 points</b>
A score of > 6 points has an unacceptable recurrence risk of 70% and should be advised to undergo open surgery (i.e. Laterjet procedure).		<b>&gt; 6 points</b>

# Bankart/Labrum repair

- RELATIEVE Indicatie:
  - ISIS <6
  - Eerste luxatie jonge patient na trauma
  - Minder dan 25% glenoid schade
  - Gefaalde conservatieve therapie

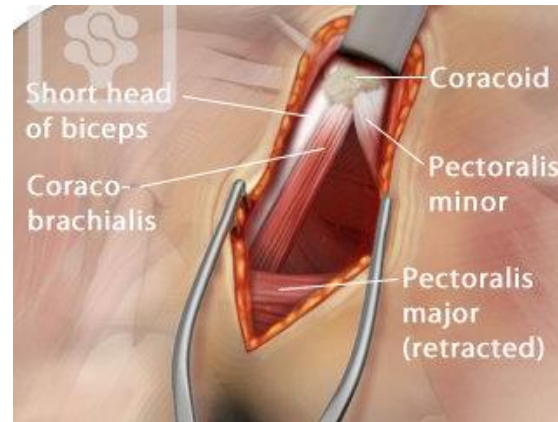
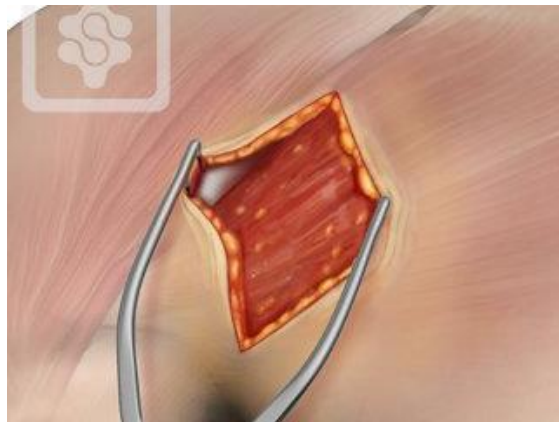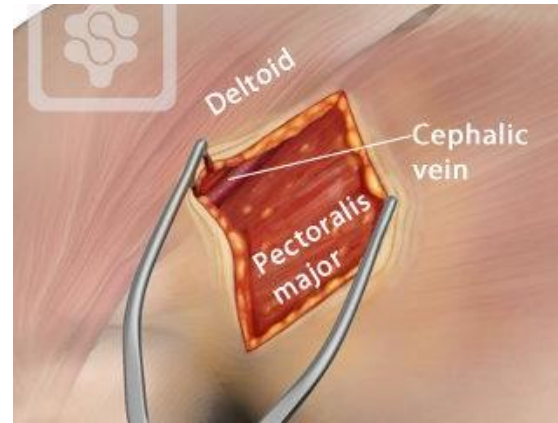
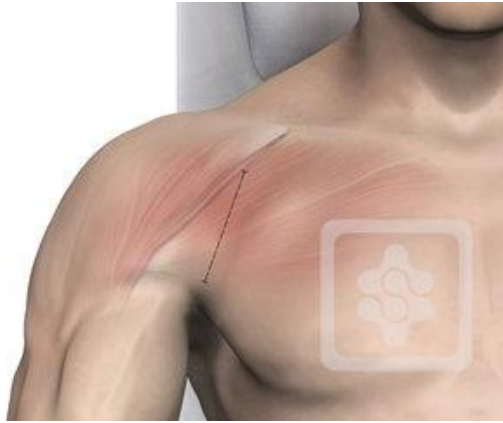# Arthroscopisch labrum herstel

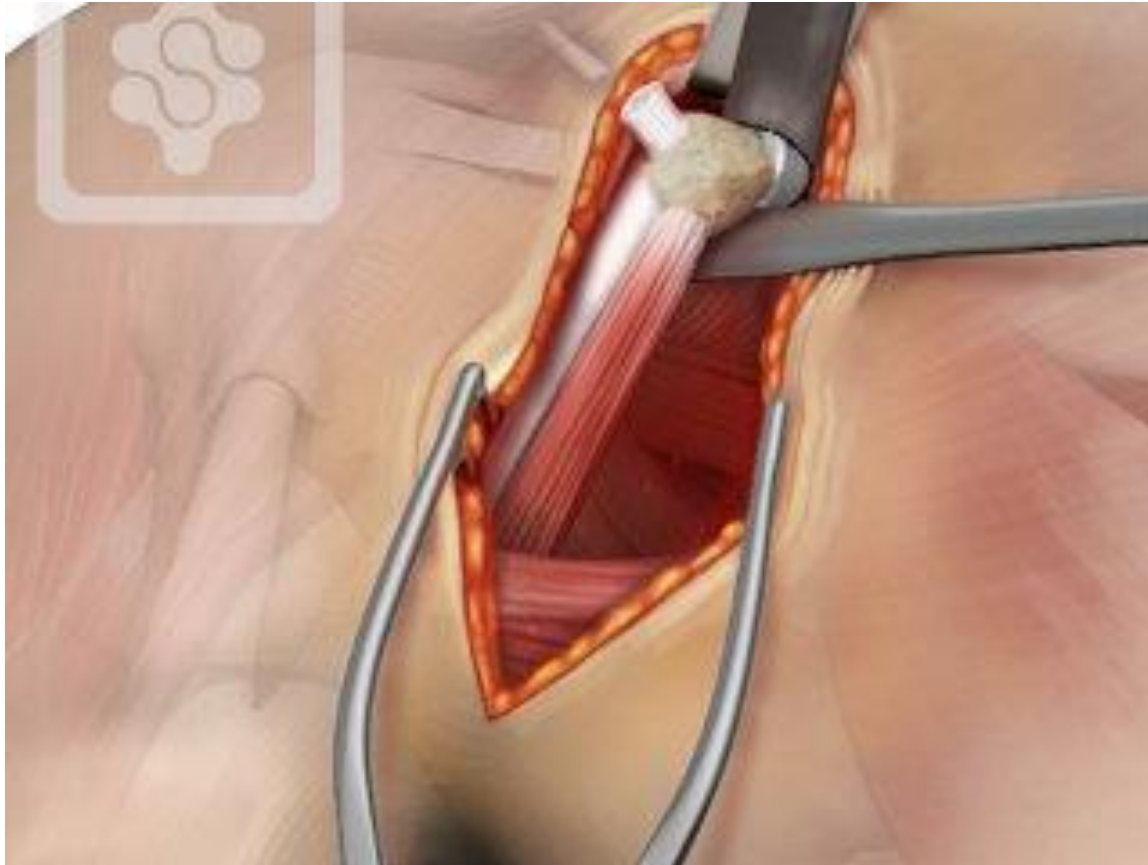


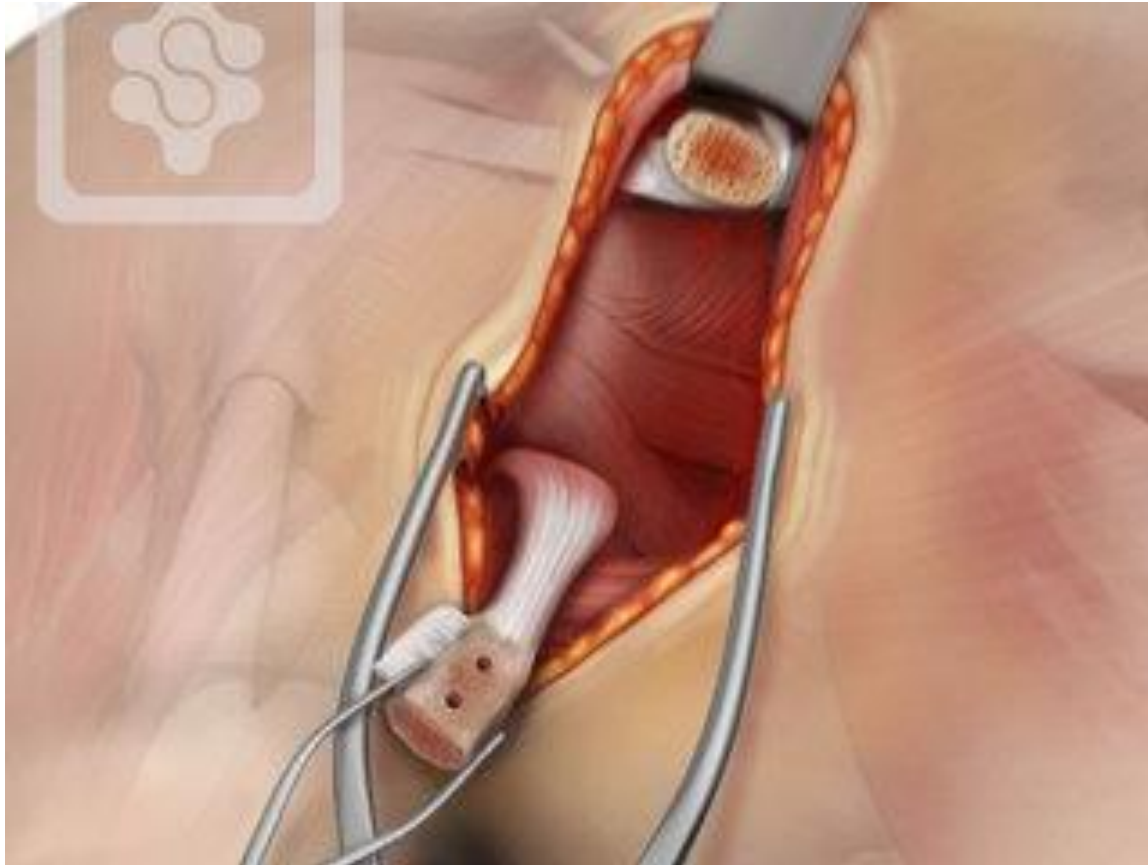# Latarjet

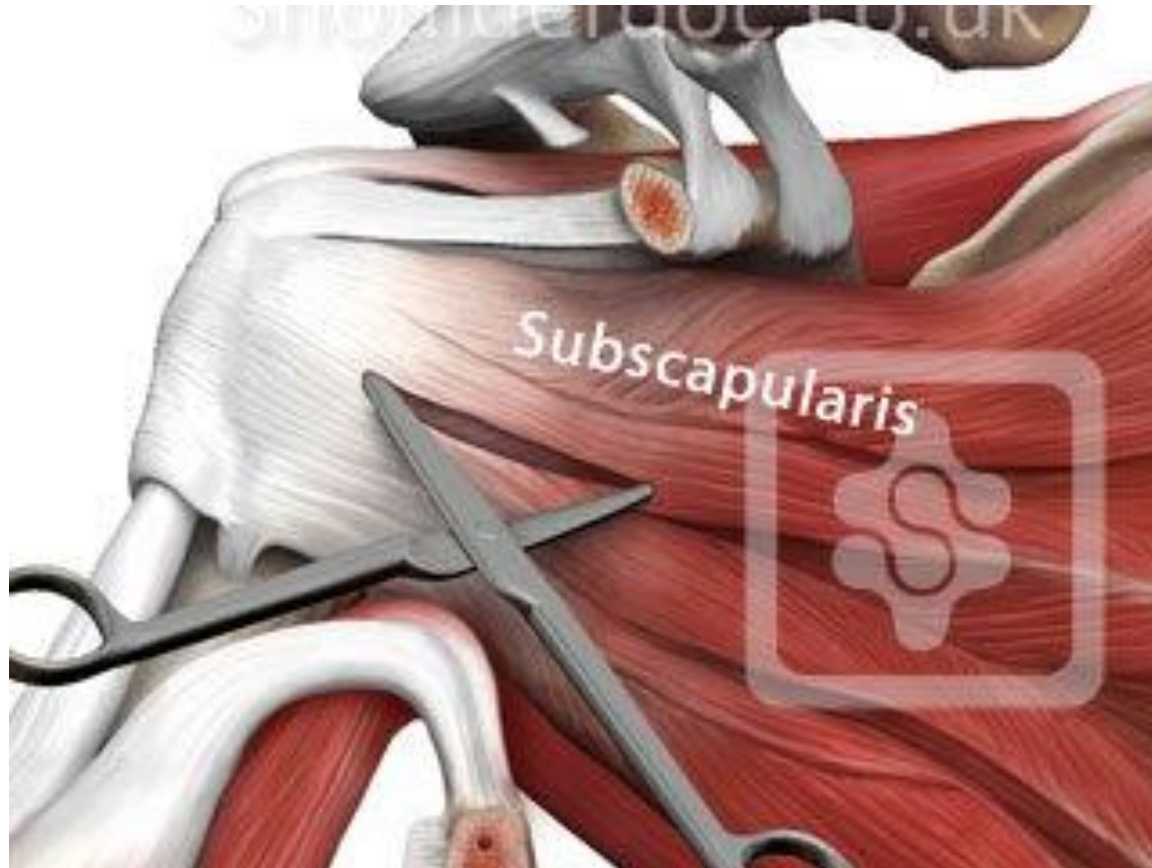- Indicatie:
  - recidiverende anterieure schouderluxaties.
  - Botverlies op het glenoid (meer dan 25% opp)
  - Instability Severity Index Score  $>6$

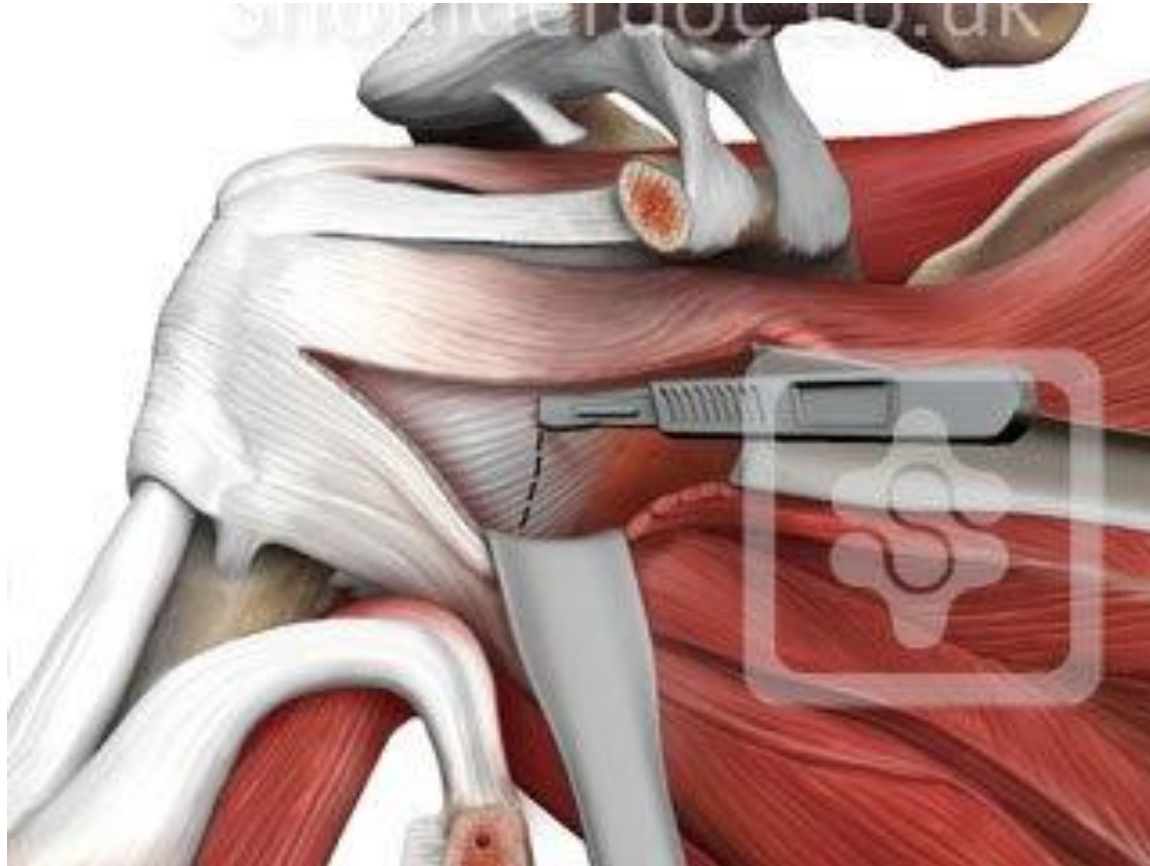


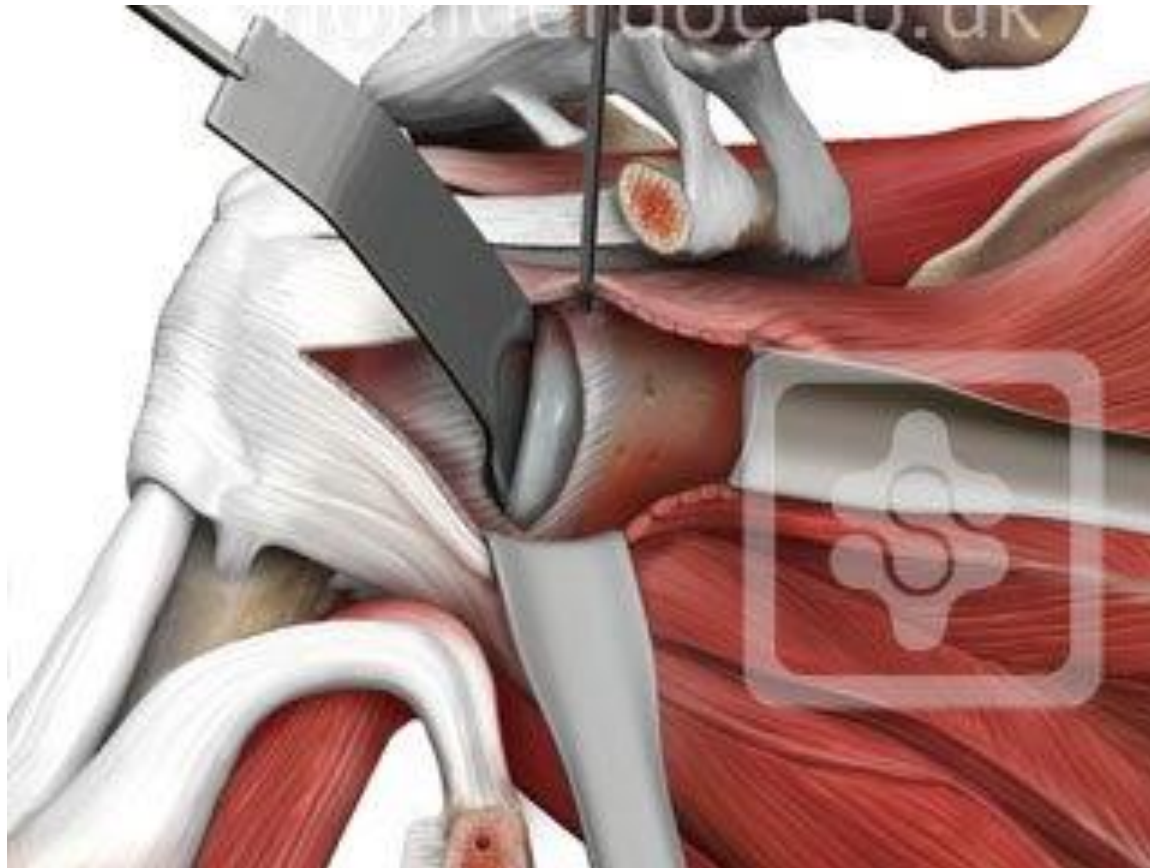


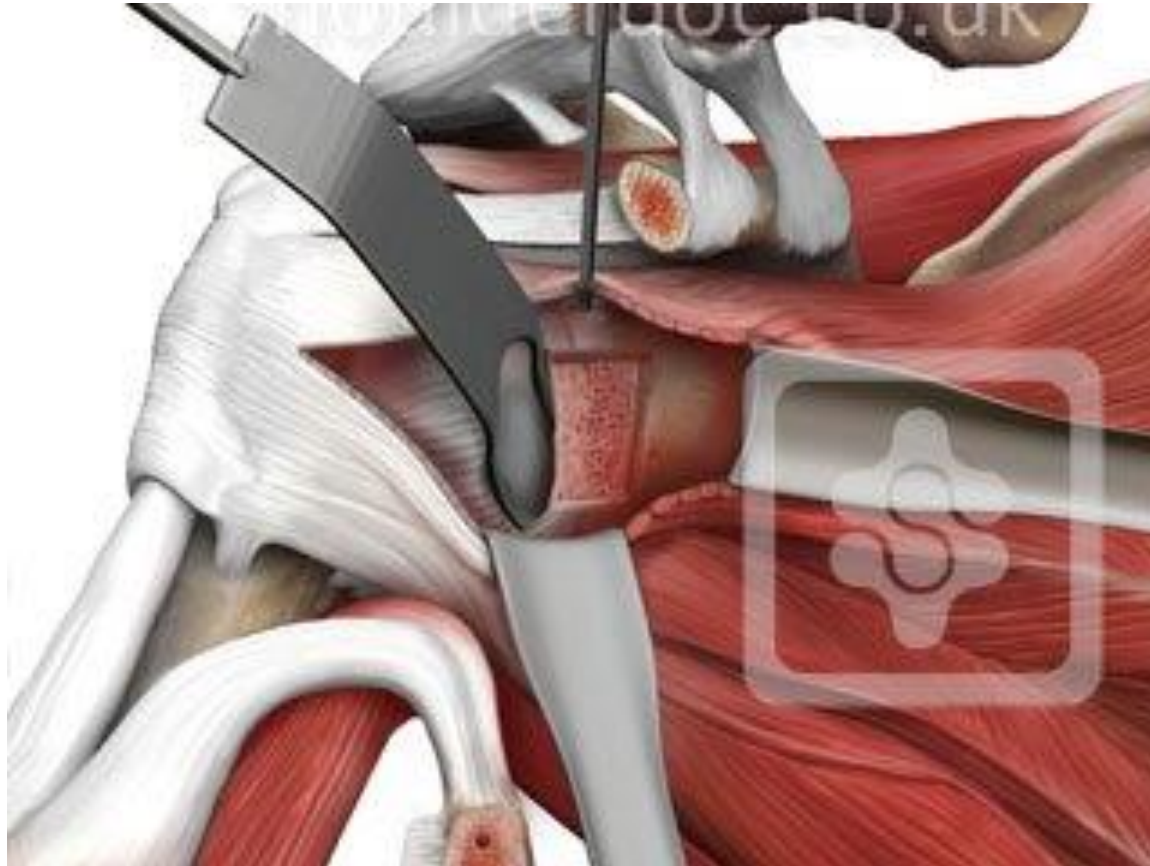


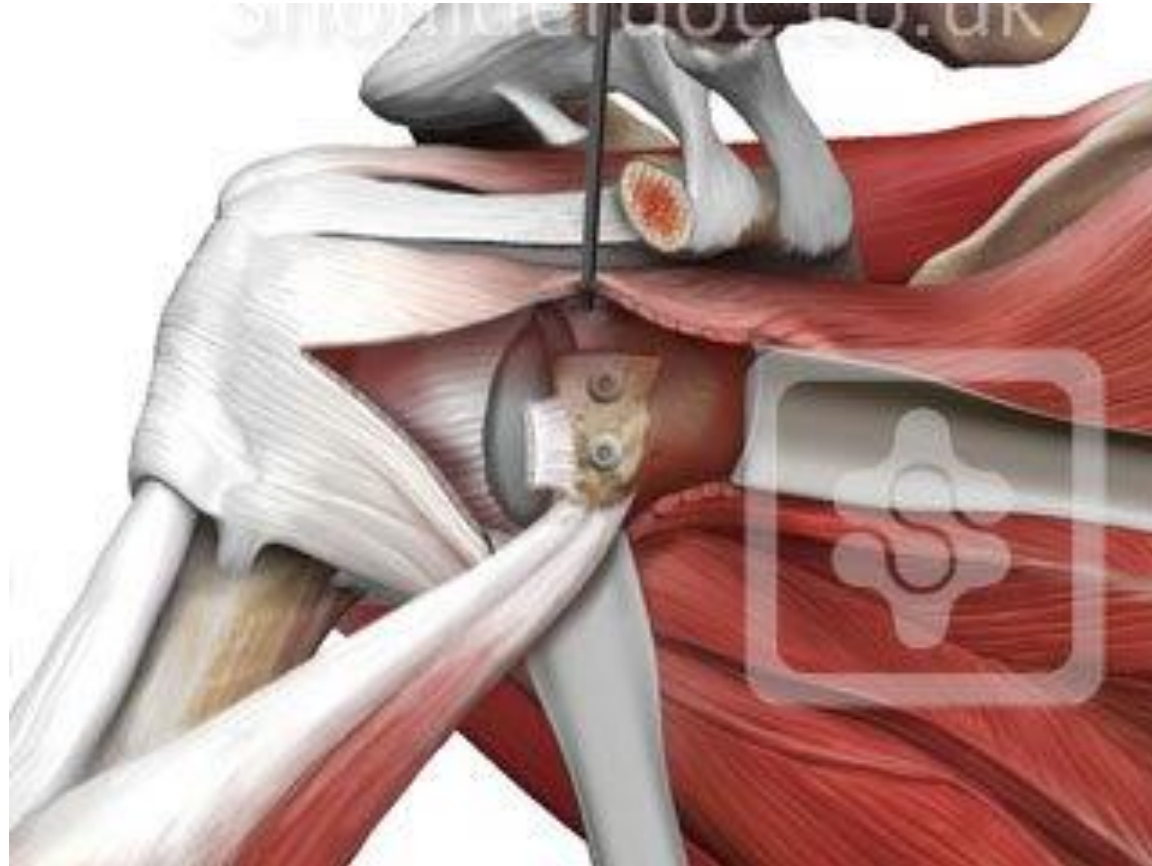




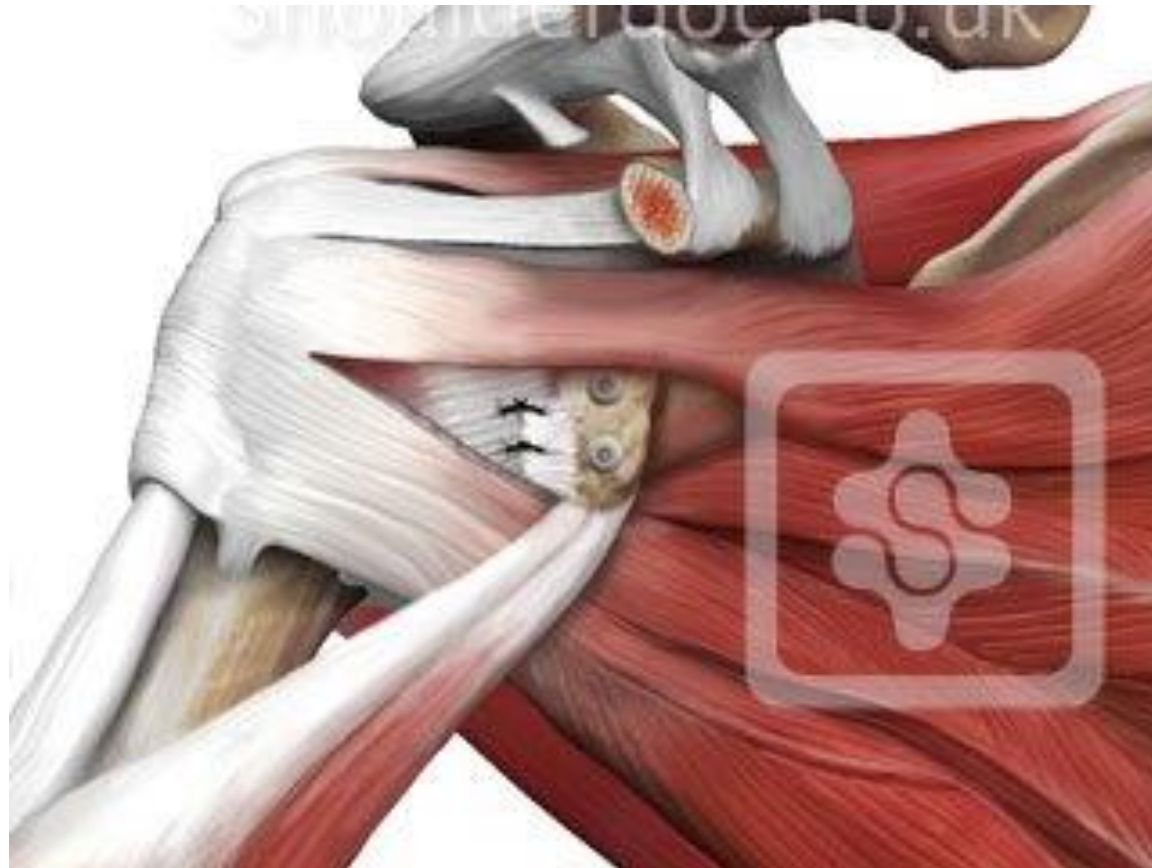

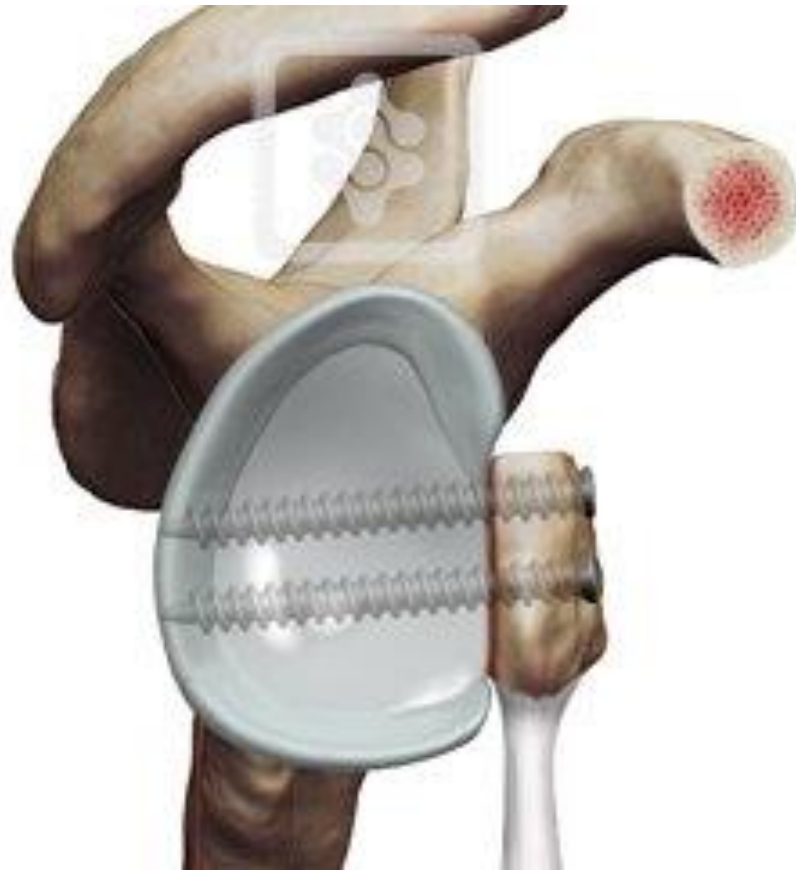





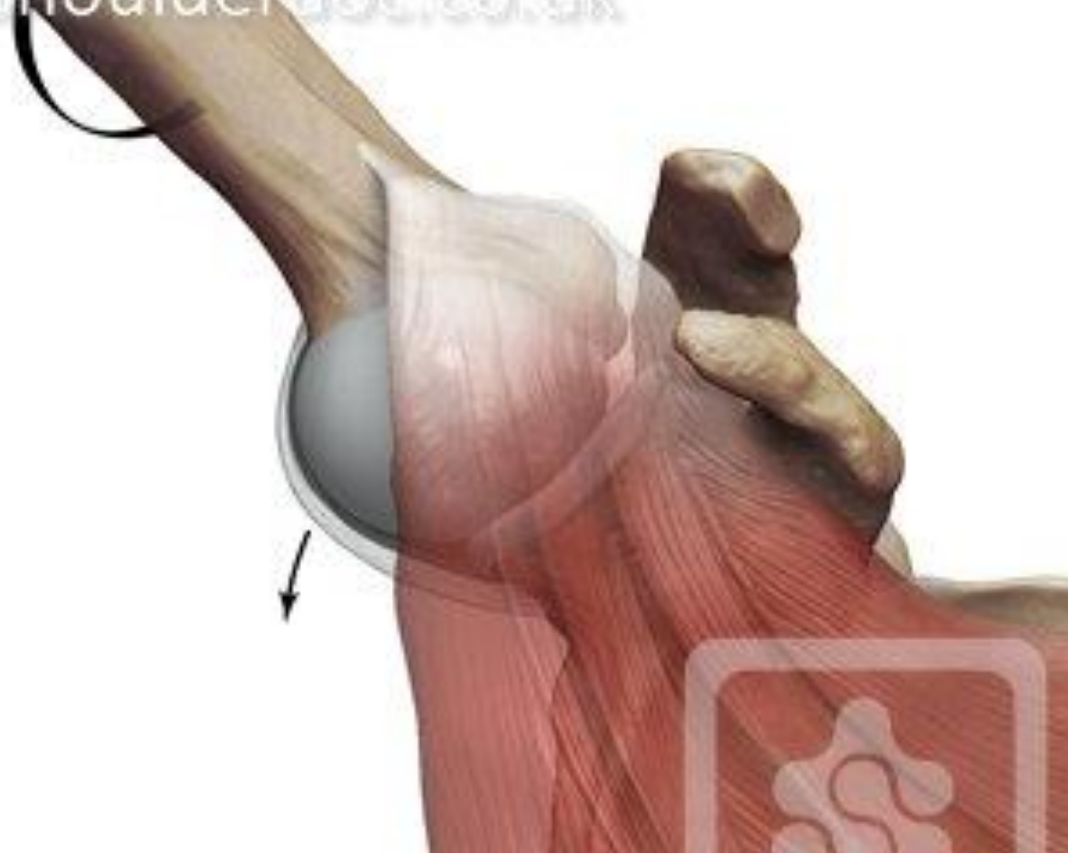




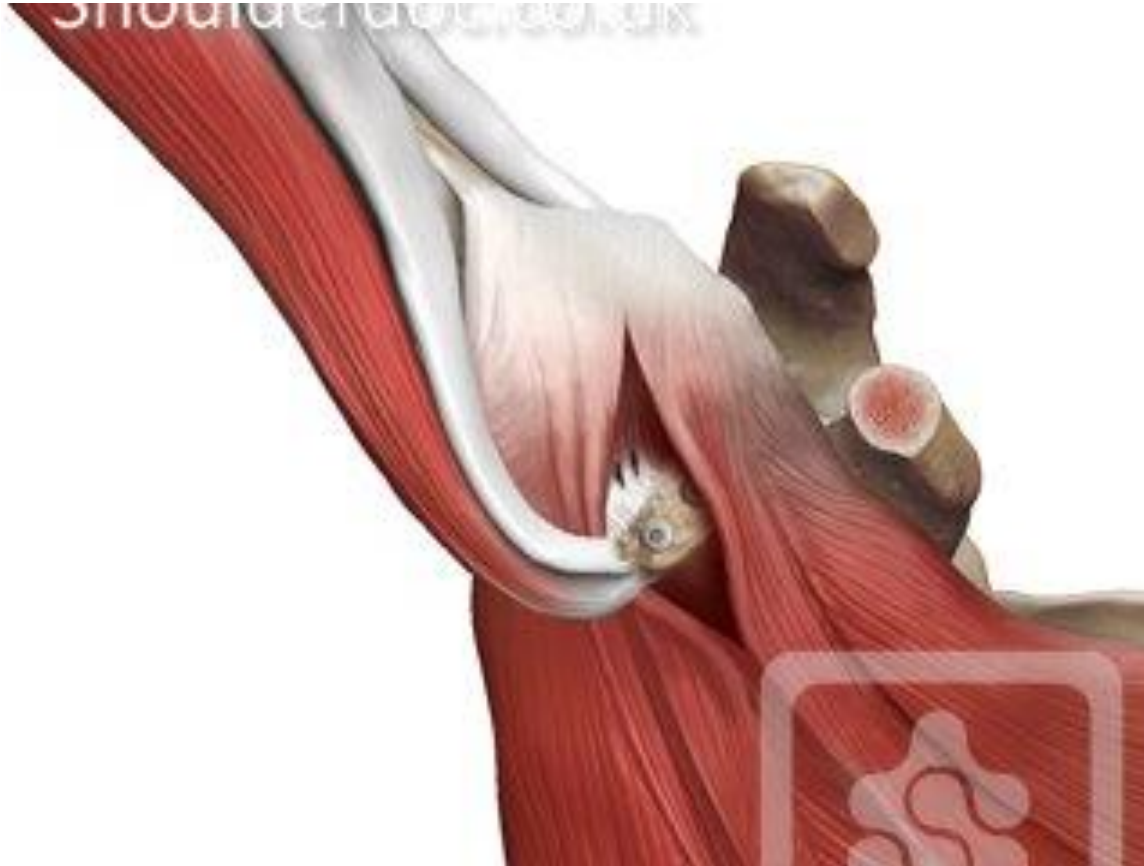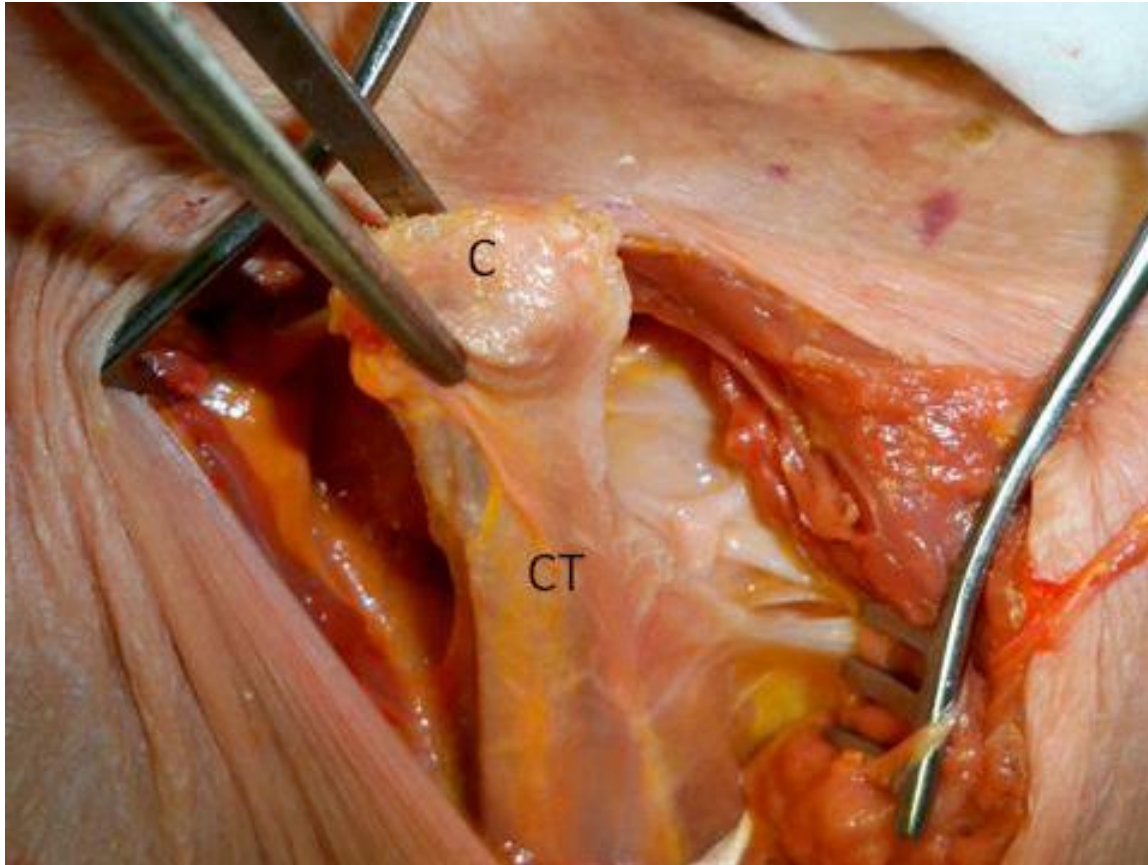


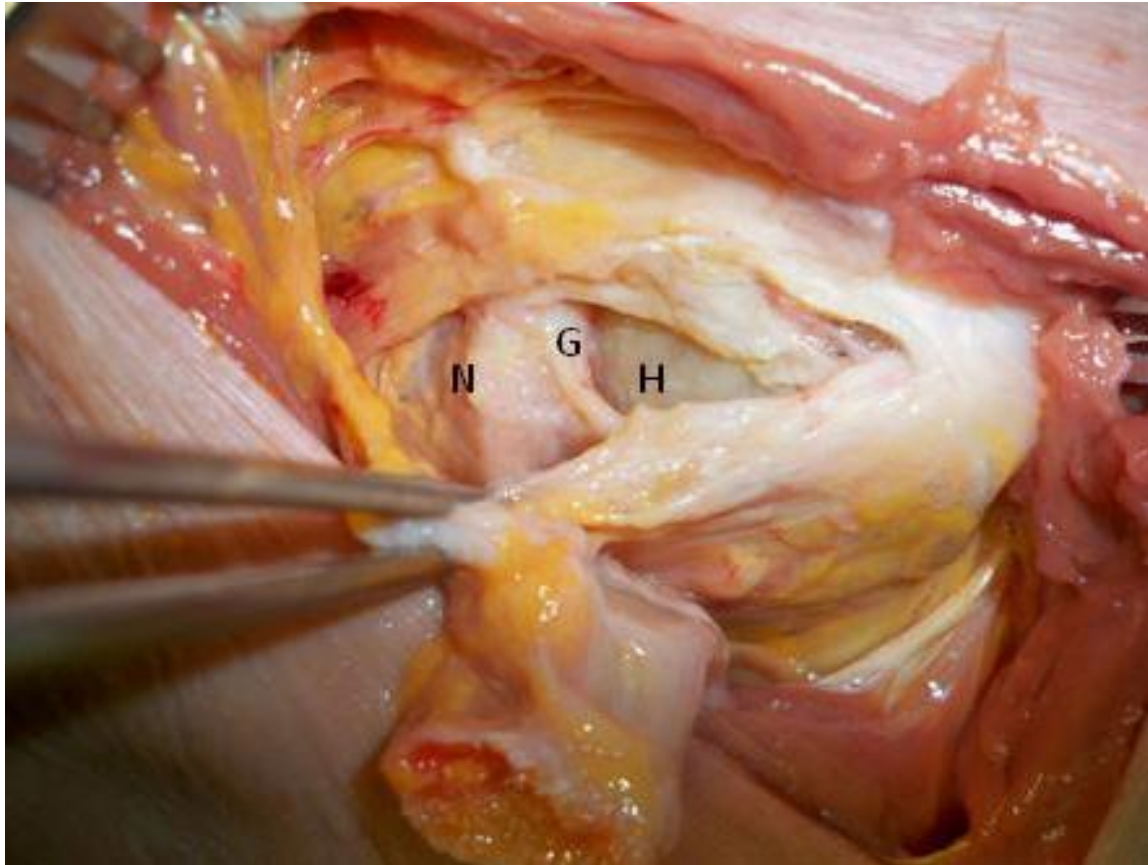
MR. J. van der Meulen

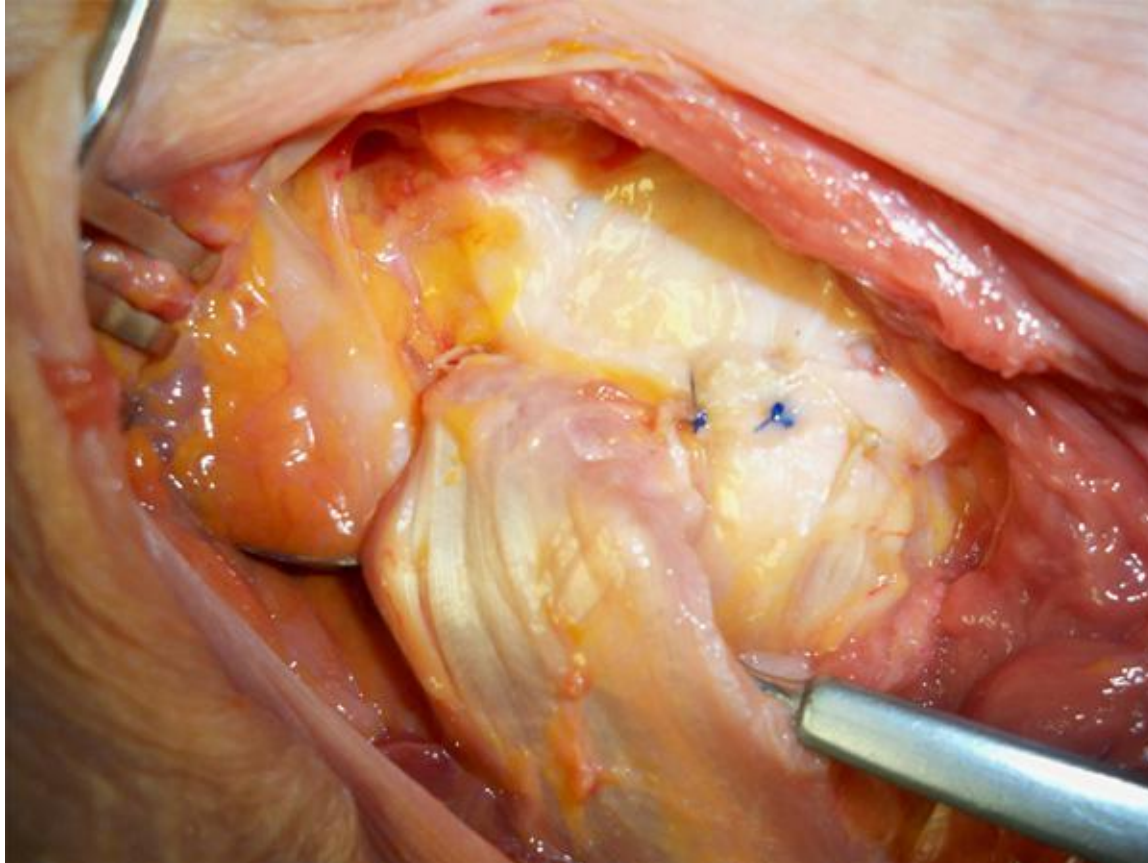


# Shoulder mechanics



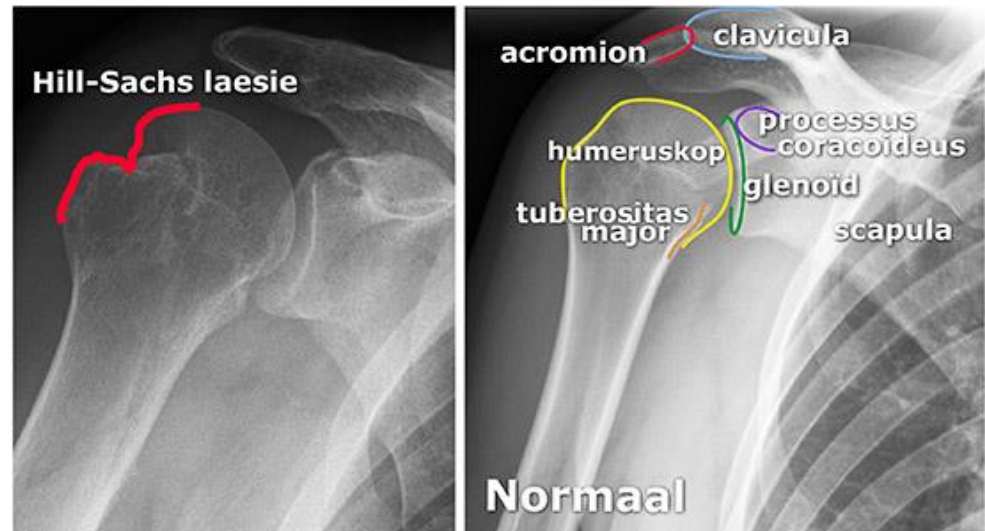






# Hill Sachs Laesie

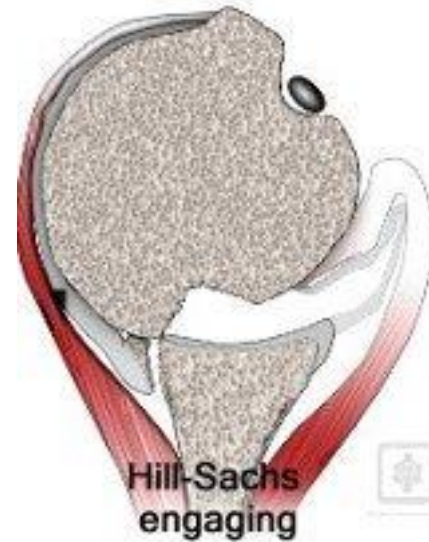
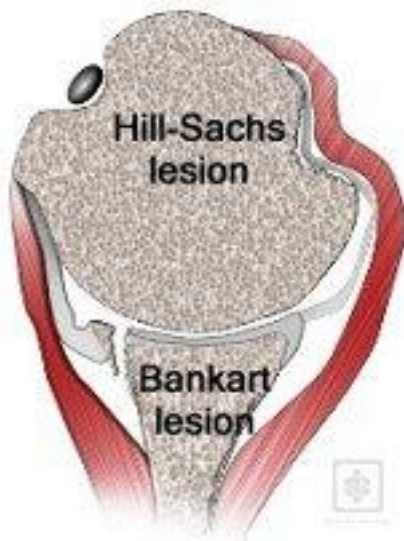
- Impressie #
- 80% vd luxaties
- Indicatie
  - >25%



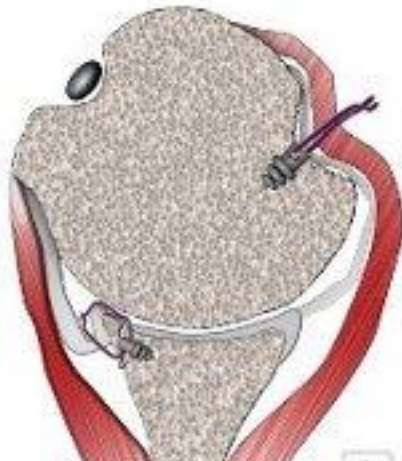- Relevant indien oorzaak luxatie



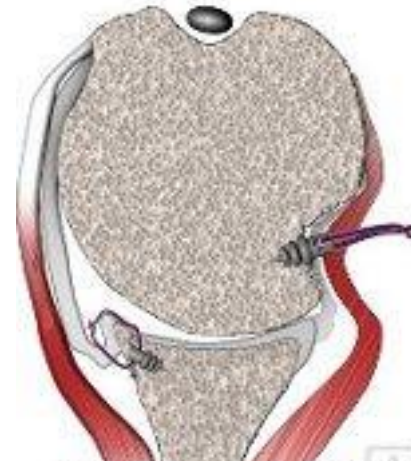# Hill Sachs Laesie



# Hill Sachs laesie



Bankart repair  
& Remplissage



Hill-Sachs unable  
to engage



**Remplissage, Labrum repair, SLAP repair**



**Dank voor uw aandacht.**

# Onze sponsors:

